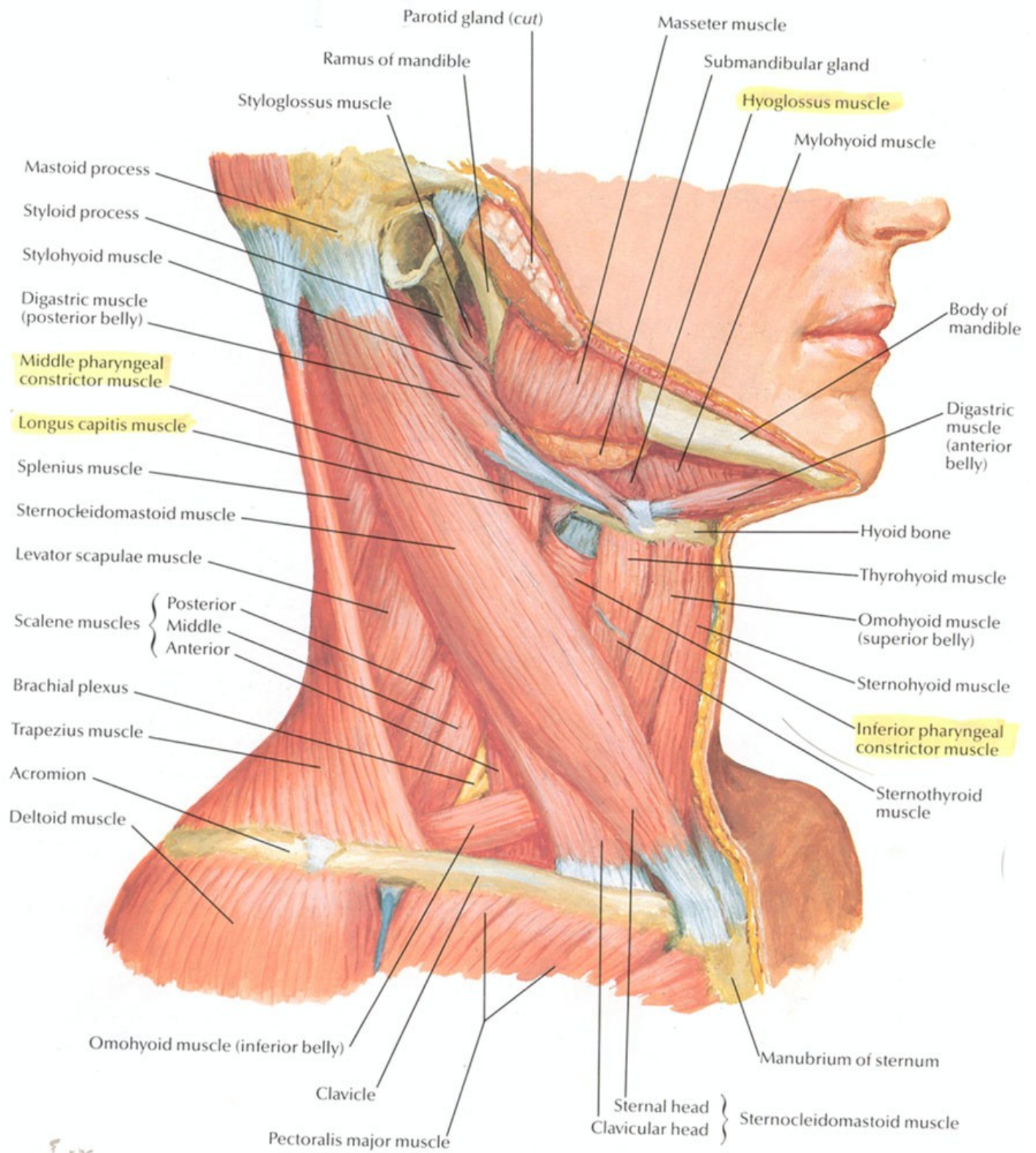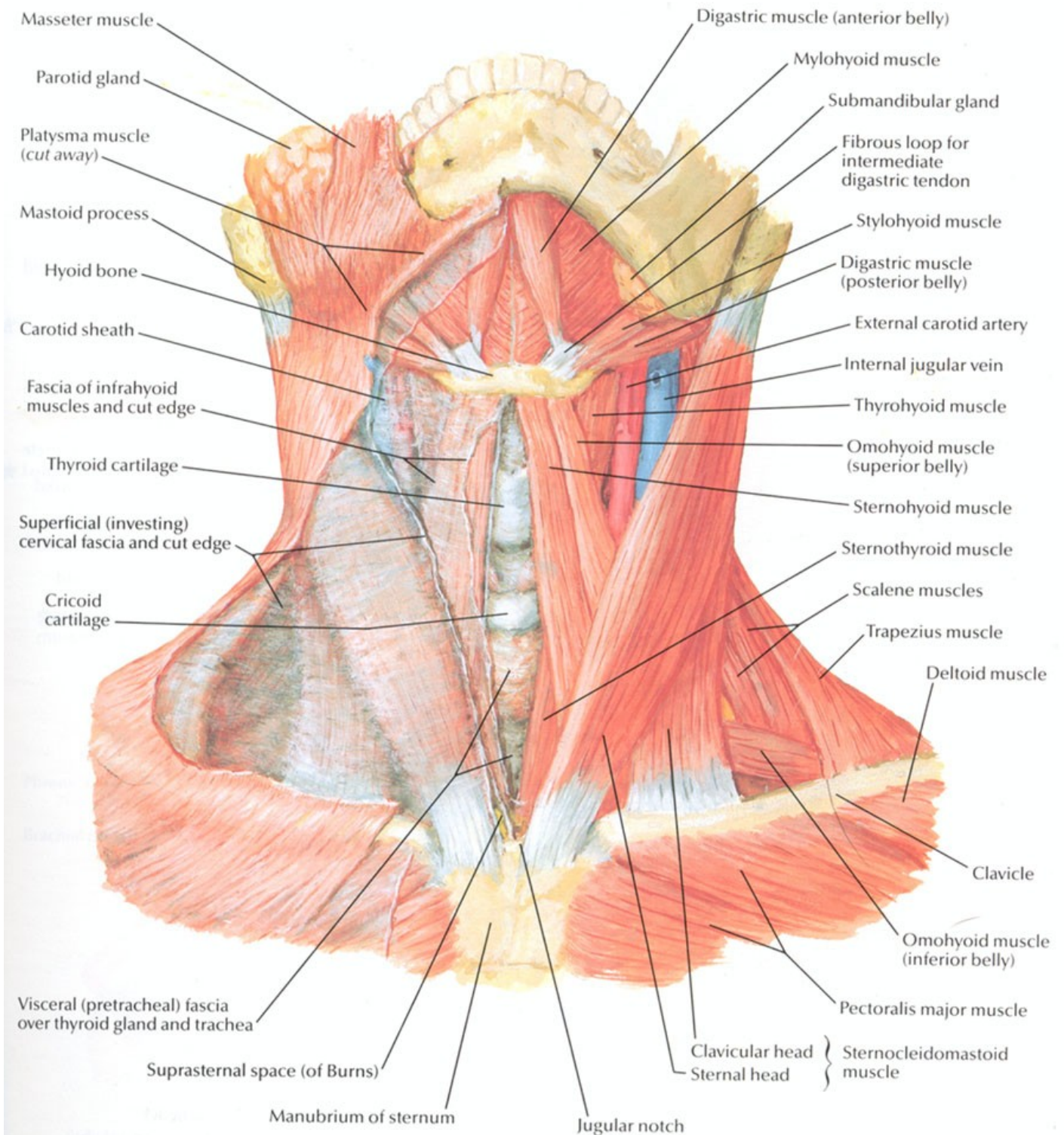
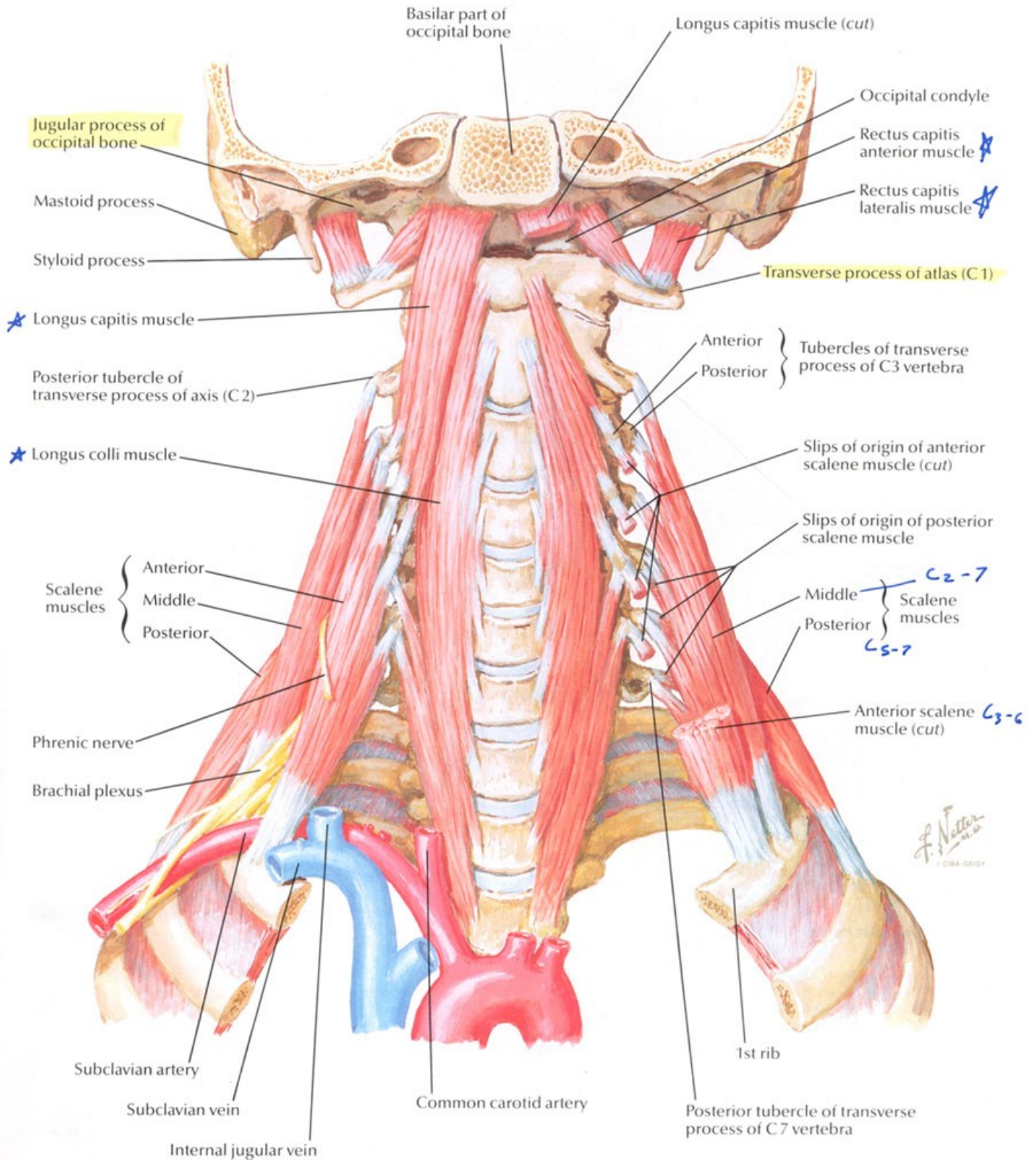


0.1.10.15

Muscles of Neck: Anterior View

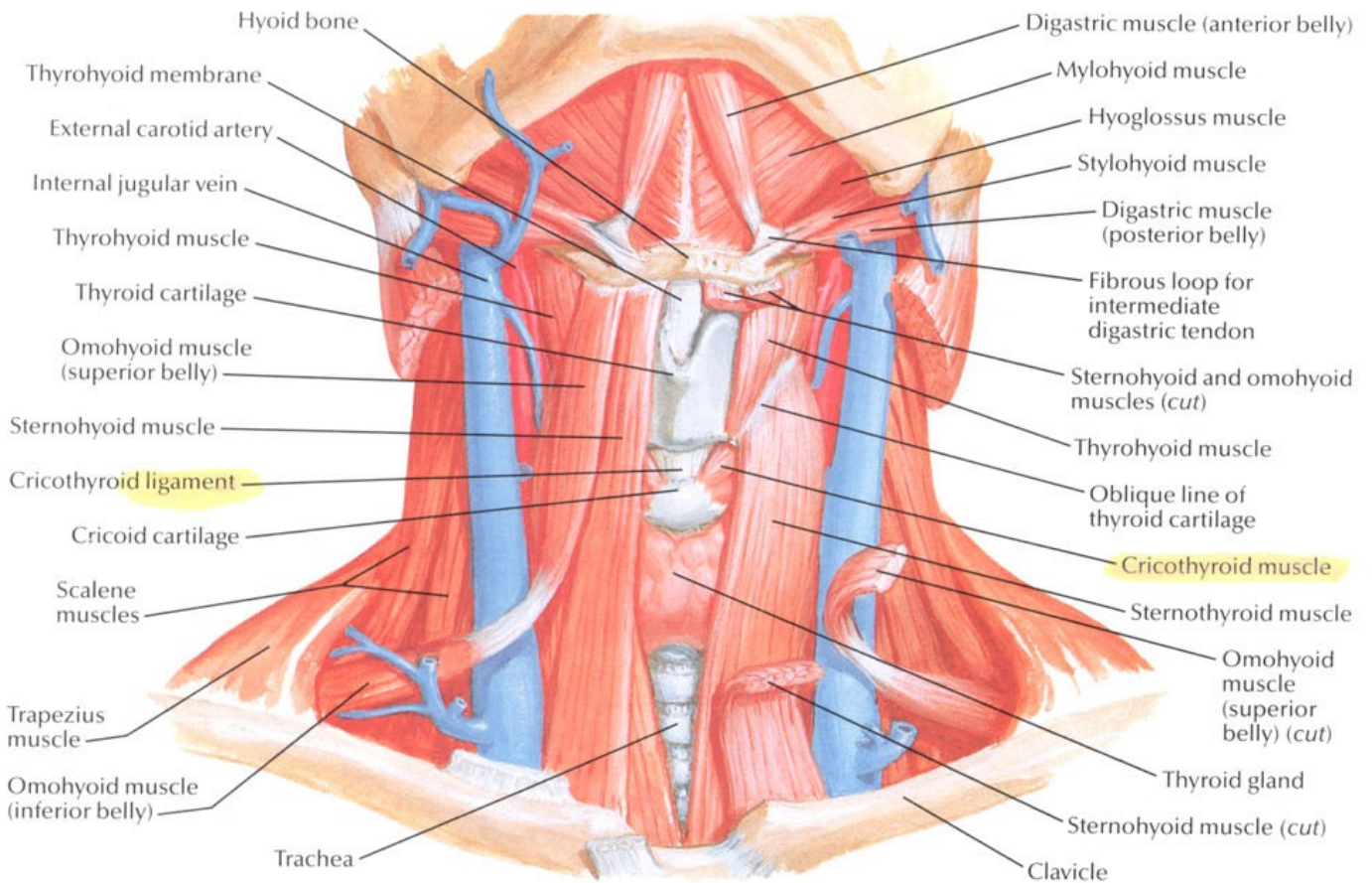


Scalene and Prevertebral Muscles

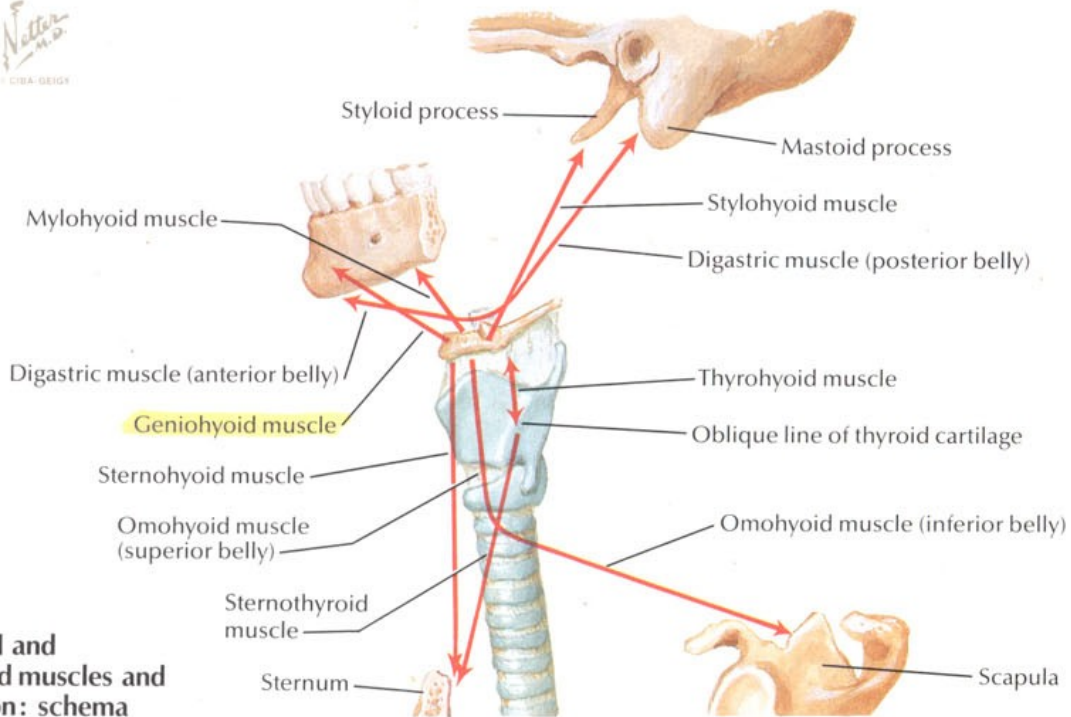


Infrahyoid and Suprahyoid Muscles

SEE ALSO PLATE 47

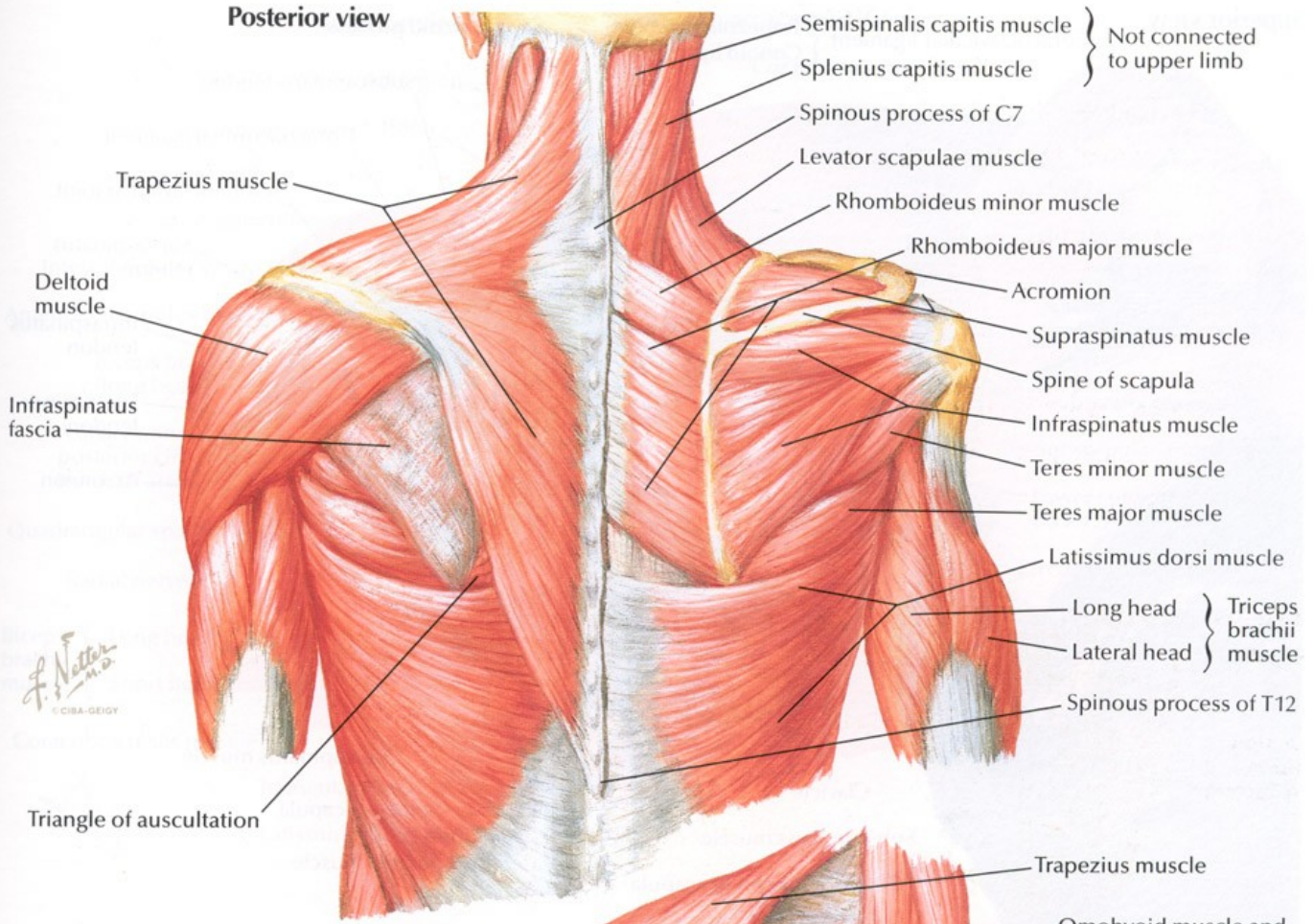


F. Netter M.D.
CIBA-GEIGY



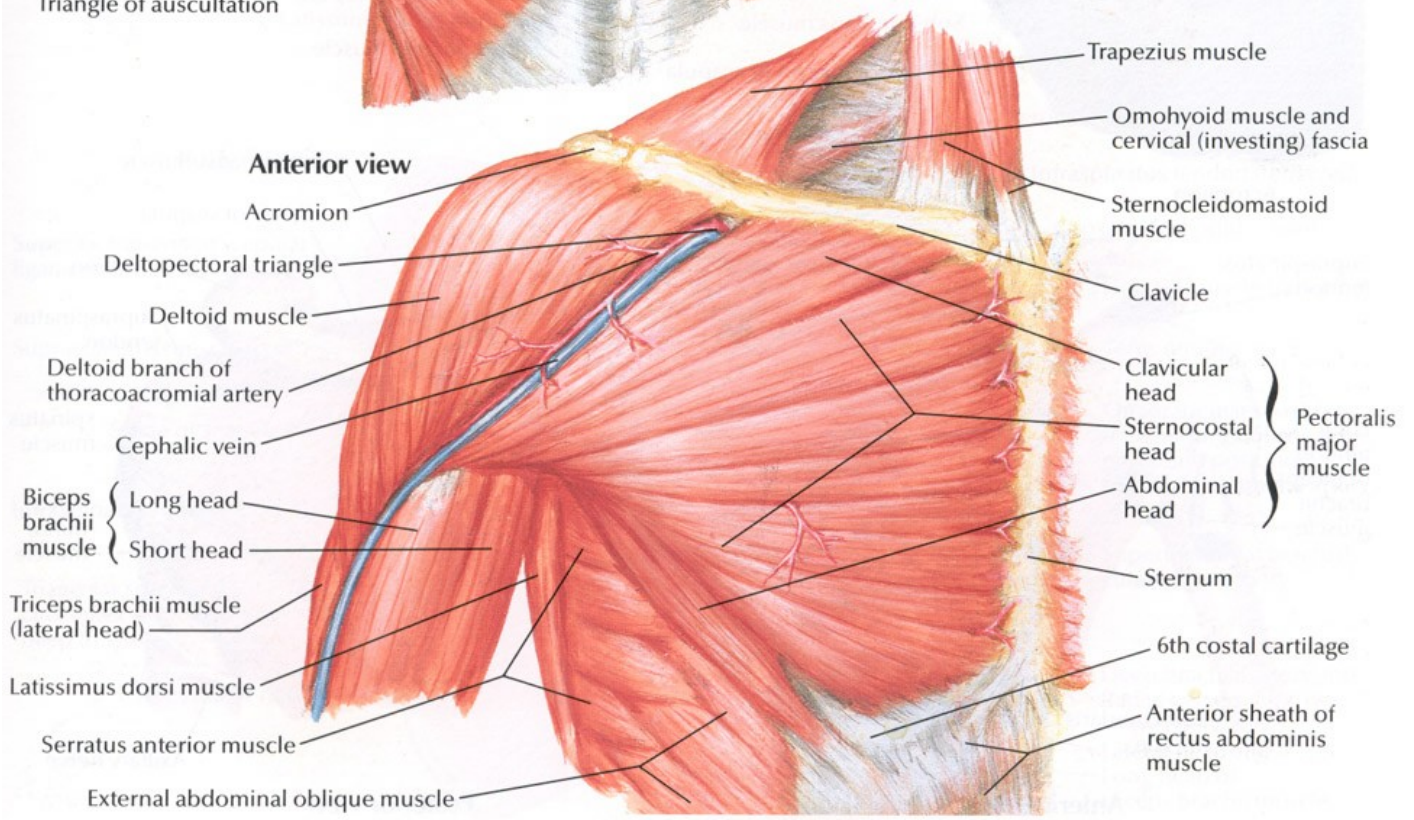
Infrahyoid and suprahyoid muscles and their action: schema

Posterior view



- Semispinalis capitis muscle } Not connected to upper limb
- Splenius capitis muscle }
- Spinous process of C7
- Levator scapulae muscle
- Rhomboideus minor muscle
- Rhomboideus major muscle
- Acromion
- Supraspinatus muscle
- Spine of scapula
- Infraspinatus muscle
- Teres minor muscle
- Teres major muscle
- Latissimus dorsi muscle
- Long head } Triceps brachii muscle
- Lateral head }
- Spinous process of T12

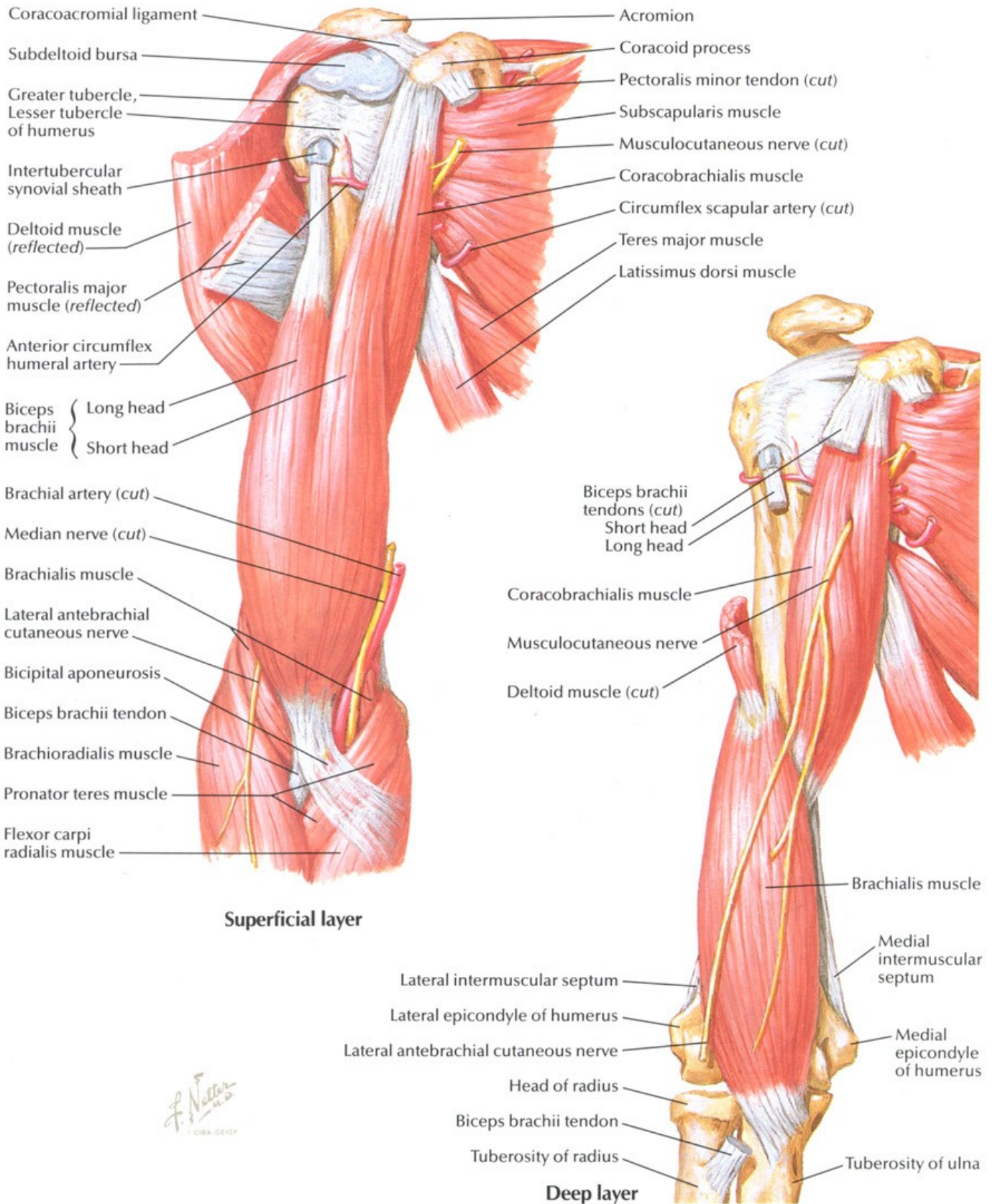
Anterior view



- Trapezius muscle
- Omohyoid muscle and cervical (investing) fascia
- Sternocleidomastoid muscle
- Clavicle
- Clavicular head } Pectoralis major muscle
- Sternocostal head }
- Abdominal head }
- Sternum
- 6th costal cartilage
- Anterior sheath of rectus abdominis muscle
- External abdominal oblique muscle
- Serratus anterior muscle
- Latissimus dorsi muscle
- Triceps brachii muscle (lateral head)
- Biceps brachii muscle { Long head
- Short head
- Cephalic vein
- Deltoid branch of thoracoacromial artery
- Deltoid muscle
- Deltopectoral triangle
- Acromion

Muscles of Arm: Anterior Views

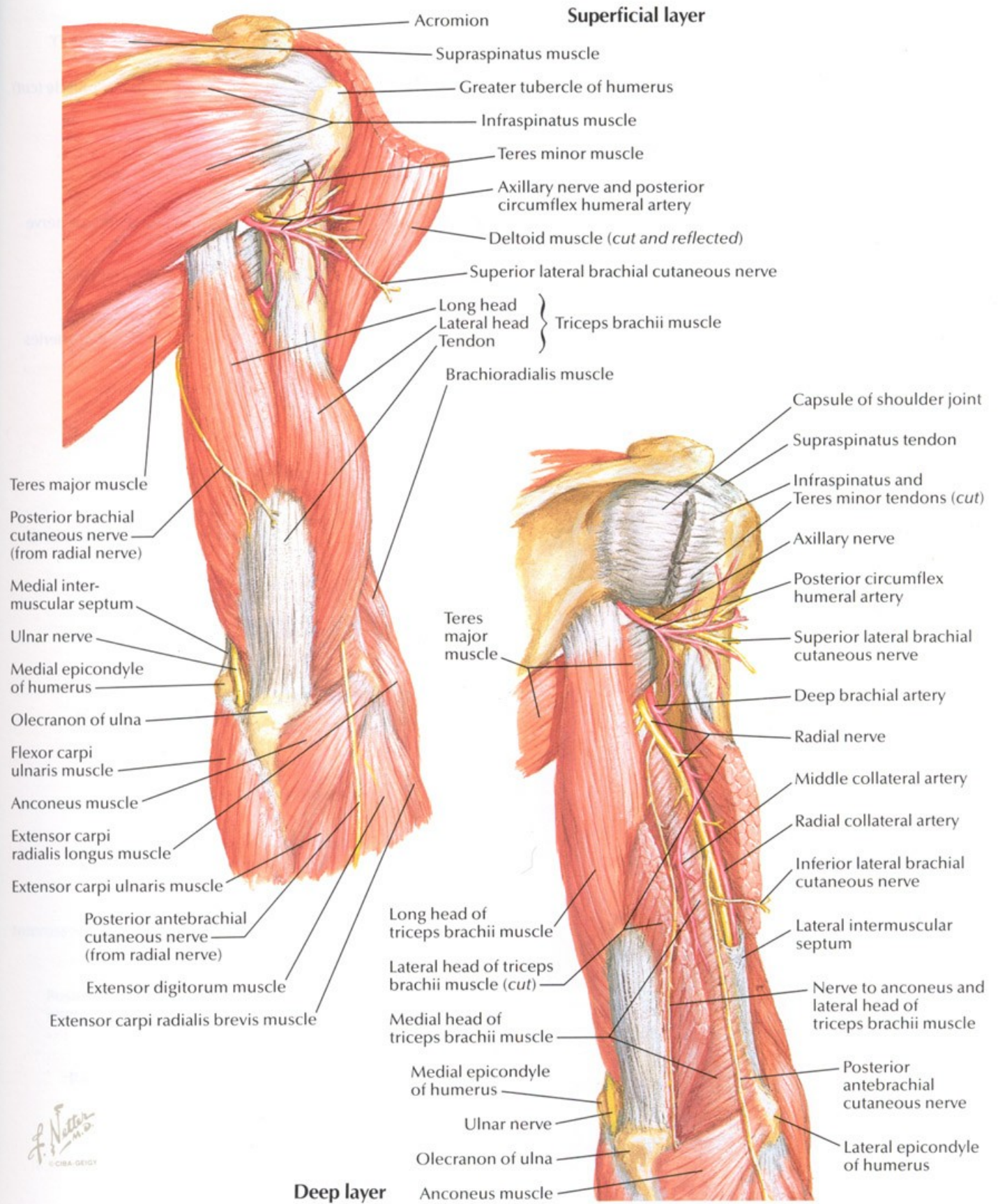
SEE ALSO PLATE 447



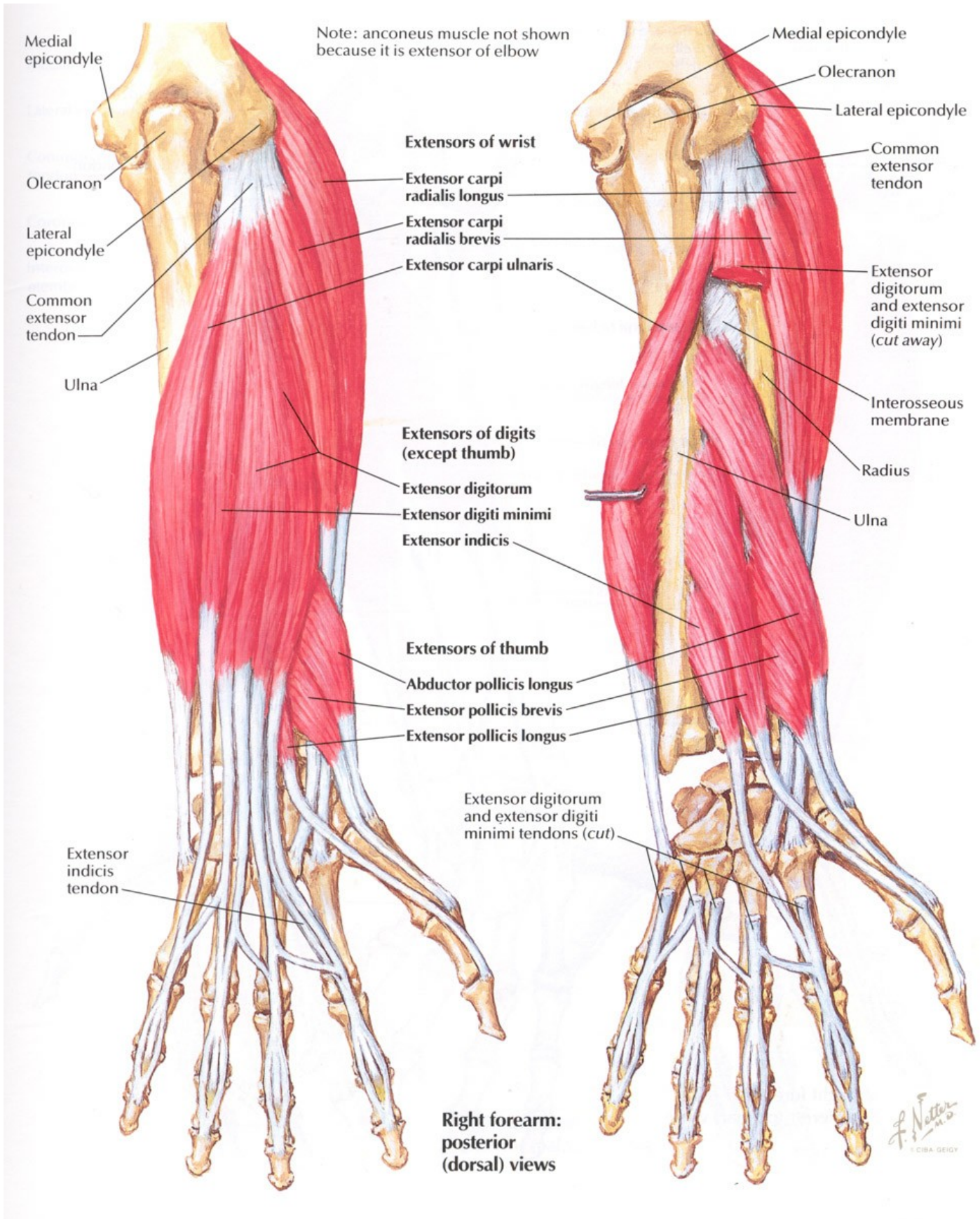
F. Netter M.D.
© CIBA-GEIGY

Muscles of Arm: Posterior Views

SEE ALSO PLATE 450



F. Netter M.D.
© CIBA-GEIGY



Right forearm: anterior view

Supination

Pronation

Lateral epicondyle

Medial epicondyle

Medial epicondyle

Lateral epicondyle

Supinator

Pronator teres

Ulna

Radius

Ulna

Radius

Pronator quadratus

F. Netter M.D.
© CIBA GEIGY

