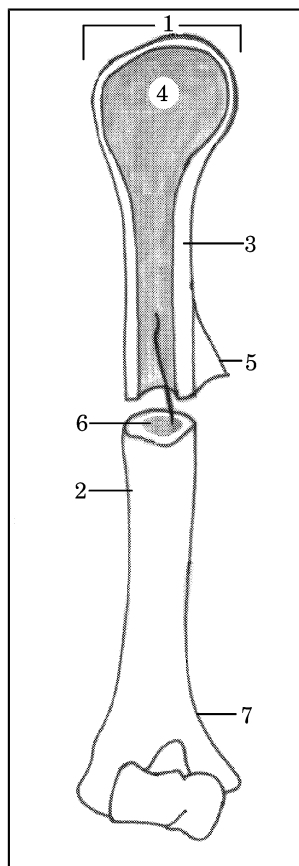


ANATOMSKE SKICE

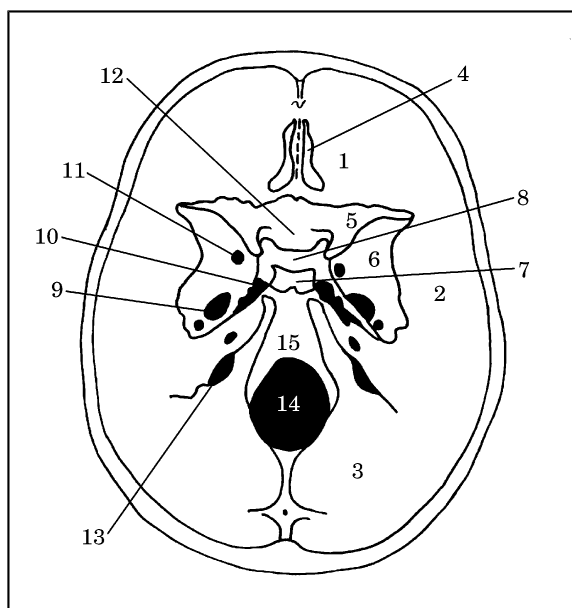
Skica 1



1. Pravilna legenda **skice 1** je:
 - A. (1) epiphysis; (3) *substantia spongiosa*; (4) *substantia compacta*; (5) *periosteum*; (7) *metaphysis*
 - B. (1) *metaphysis*; (3) *substantia compacta*; (4) *substantia spongiosa*; (5) *epiphysis*; (7) *periosteum*
 - C. (1) *epiphysis*; (3) *substantia compacta*; (4) *substantia spongiosa*; (5) *periosteum*; (7) *metaphysis*
 - D. (1) *epiphysis*; (3) *substantia compacta*; (4) *substantia spongiosa*; (5) *periosteum*; (7) *metaphysis*
 - E. (3) *substantia compacta*; (4) *epiphysis*; (5) *substantia spongiosa*; (6) *metaphysis*; (7) *periosteum*.

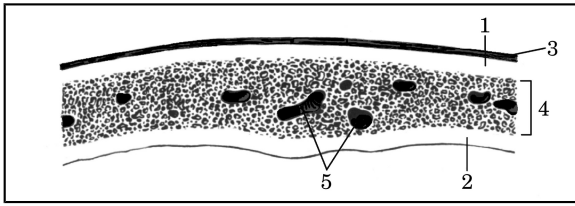
2. Pravilna legenda **skice 1** je:
 - A. (2) *diaphysis*; (4) *substantia spongiosa*; (6) *cavum medullare (medulla ossium flava)*; (7) *metaphysis*
 - B. (2) *metaphysis*; (4) *substantia spongiosa*; (6) *cavum medullare*; (7) *diaphysis*; (*medulla ossium flava*)

- C. (2) *diaphysis*; (4) *cavum medullare (medulla ossium flava)*; (6) *substantia spongiosa*; (7) *metaphysis*
- D. (1) *cavum medullare (medulla ossium flava)*; (2) *diaphysis*; (4) *substantia spongiosa*; (7) *metaphysis*
- E. (2) *diaphysis*; (4) *substantia spongiosa*; (5) *cavum medullare (medulla ossium flava)*; (6) *metaphysis*.



Skica 2

3. Pravilna legenda **skice 2** je:
 - A. Lobanjsko dno – od spodaj (*basis cranii*), (1) *fossa cranii anterior*; (3) *ala minor*; (5) *foramen ovale*; (7) *dorsum sellae*; (9) *fossa cranii posterior*
 - B. Lobanjsko dno – od zgoraj (*basis cranii*), (1) *fossa cranii anterior*; (3) *fossa cranii posterior*; (5) *ala minor*; (7) *dorsum sellae*; (9) *foramen ovale*
 - C. Lobanjsko dno – od zgoraj (*basis cranii*), (1) *fossa cranii posterior*; (3) *fossa cranii anterior*; (5) *dorsum sellae*; (7) *ala minor*; (9) *foramen ovale*;
 - D. Lobanjsko dno – od zgoraj (*basis cranii*), (1) *fossa cranii anterior*; (3) *fossa cranii posterior*; (5) *ala minor*; (9) *dorsum sellae*; (13) *foramen ovale*



- E. Lobanjsko dno – od spodaj (*basis cranii*), (1) *fossa cranii anterior*; (5) *ala minor*; (7) *dorsum sellae*; (9) *foramen ovale*, (15) *fossa cranii posterior*.

4. Pravilna legenda **skice 2** je:

- A. Lobanjsko dno – od spodaj (*basis cranii*), (2) *clivus*; (4) *lamina cribrosa (os ethmoidale)*; (6) *ala major*; (8) *fossa hypophysialis*; (15) *fossa cranii media*
- B. Lobanjsko dno – od zgoraj (*basis cranii*), (2) *fossa cranii media*; (4) *lamina cribrosa (os ethmoidale)*; (6) *fossa hypophysialis*; (8) *ala major*; (15) *clivus*
- C. Lobanjsko dno – od spodaj (*basis cranii*), (2) *fossa cranii media*; (4) *lamina cribrosa (os ethmoidale)*; (6) *clivus*; (8) *fossa hypophysialis*; (15) *ala major*
- D. Lobanjsko dno – od zgoraj (*basis cranii*), (2) *lamina cribrosa (os ethmoidale)*; (4) *fossa cranii media*; (6) *ala major*; (8) *fossa hypophysialis*; (15) *clivus*
- E. Lobanjsko dno – od zgoraj (*basis cranii*), (2) *fossa cranii media*; (4) *lamina cribrosa (os ethmoidale)*; (6) *ala major*; (8) *fossa hypophysialis*; (15) *clivus*.

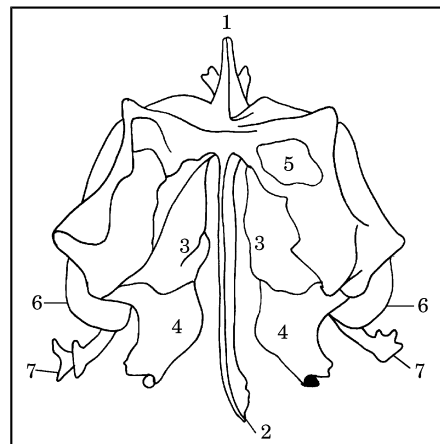
5. Pravilna legenda **skice 2** je:

- A. Lobanjsko dno – od zgoraj (*basis cranii*), (10) *foramen lacerum*; (11) *sulcus chiasmatis*; (12) *foramen rotundum*; (13) *foramen jugulare*; (14) *foram magnum*
- B. Lobanjsko dno – od spodaj (*basis cranii*), (10) *foram magnum*; (11) *foramen rotundum*; (12) *sulcus chiasmatis*; (13) *foramen jugulare*; (14) *foramen lacerum*
- C. Lobanjsko dno – od zgoraj (*basis cranii*), (10) *foramen jugulare*; (11) *foramen rotundum*; (12) *sulcus chiasmatis*; (13) *foramen lacerum*; (14) *foram magnum*
- D. Lobanjsko dno – od zgoraj (*basis cranii*), (10) *foramen lacerum*; (11) *foramen rotundum*; (12) *sulcus chiasmatis*; (13) *foramen jugulare*; (14) *foram magnum*
- E. Lobanjsko dno – od zgoraj (*basis cranii*), (10) *foramen lacerum*; (11) *foramen rotundum*; (12) *sulcus chiasmatis*; (13) *foram magnum*; (14) *foramen jugulare*.

Skica 3

6. Pravilna legenda **skice 3** je:

- A. (1) *lamina interna*; (2) *lamina externa*; (3) *diploë*; (4) *periosteum*; (5) *canales diploici*
- B. (1) *lamina externa*; (2) *lamina interna*; (3) *periosteum*; (4) *diploë*; (5) *canales diploici*
- C. (1) *lamina externa*; (2) *lamina interna*; (3) *diploë*; (4) *periosteum*; (5) *canales diploici*
- D. (1) *lamina interna*; (2) *lamina externa*; (3) *periosteum*; (4) *diploë*; (5) *canales diploici*
- E. (1) *canales diploici*; (2) *lamina interna*; (3) *periosteum*; (4) *diploë*; (5) *lamina externa*.

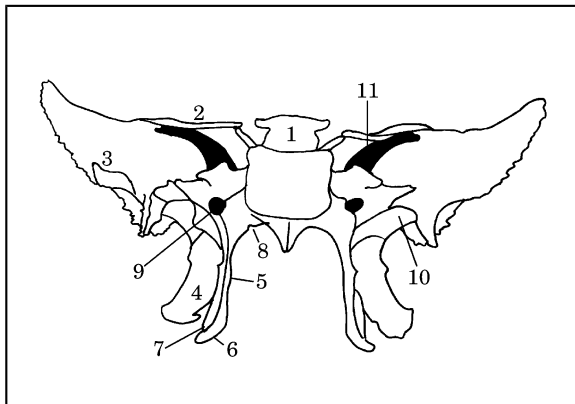


Skica 4

7. Pravilna legenda **skice 4** je:

- A. Sitka – od zgoraj (*os ethmoidale*), (1) *processus uncinatus*; (3) *concha nasalis superior*; (4) *concha nasalis media*; (5) *cellulae ethmoidales*; (7) *crista galli*
- B. Sitka – od zgoraj (*os ethmoidale*), (1) *crista galli*; (3) *concha nasalis superior*; (4) *concha nasalis media*; (5) *cellulae ethmoidales*; (7) *processus uncinatus*
- C. Sitka – od zgoraj (*os ethmoidale*), (1) *crista galli*; (3) *concha nasalis media*; (4) *concha nasalis superior*; (5) *cellulae ethmoidales*; (7) *processus uncinatus*
- D. Sitka – od zgoraj (*os ethmoidale*), (1) *crista galli*; (3) *concha nasalis superior*; (4) *cellulae ethmoidales*; (5) *concha nasalis media*; (7) *processus uncinatus*

- E. Sitka – od zgoraj (*os ethmoidale*), (1) *concha nasalis superior*; (3) *crista galli*; (4) *concha nasalis media*; (5) *cellulae ethmoidales*; (7) *processus uncinatus*.
8. Pravilna legenda **skice 4** je:
- A. Sitka – od zgoraj (*os ethmoidale*), (2) *bullae ethmoidalis*; (3) *concha nasalis superior*; (4) *concha nasalis media*; (5) *cellulae ethmoidales*; (6) *lamina perpendicularis*
- B. Sitka – od zgoraj (*os ethmoidale*), (2) *lamina perpendicularis*; (3) *cellulae ethmoidales*; (4) *concha nasalis media*; (5) *concha nasalis superior*; (6) *bullae ethmoidalis*
- C. Sitka – od zgoraj (*os ethmoidale*), (2) *lamina perpendicularis*; (3) *concha nasalis superior*; (4) *bullae ethmoidalis*; (5) *cellulae ethmoidales*; (6) *concha nasalis media*
- D. Sitka – od zgoraj (*os ethmoidale*), (2) *lamina perpendicularis*; (3) *concha nasalis superior*; (4) *concha nasalis media*; (5) *cellulae ethmoidales*; (6) *bullae ethmoidalis*
- E. Sitka – od spodaj (*os ethmoidale*), (2) *lamina perpendicularis*; (3) *concha nasalis superior*; (4) *concha nasalis media*; (5) *cellulae ethmoidales*; (6) *bullae ethmoidalis*.
- C. (3) *fossa scaphoidea*; (4) *lamina lateralis processus pterygoidei*; (5) *lamina medialis processus pterygoidei*; (6) *hamulus pterygoideus*; (8) *processus vaginalis*; (10) *ala major*
- D. (3) *lamina medialis processus pterygoidei*; (4) *lamina lateralis processus pterygoidei*; (5) *ala major*; (6) *hamulus pterygoideus*; (8) *processus vaginalis*; (10) *fossa scaphoidea*
- E. (3) *hamulus pterygoideus*; (4) *lamina lateralis processus pterygoidei*; (5) *lamina medialis processus pterygoidei*; (6) *ala major*; (8) *processus vaginalis*; (10) *fossa scaphoidea*.
10. Pravilna legenda **skice 5** je:
- A. (1) *dorsum sellae*; (2) *incisura pterygoidea*; (5) *lamina medialis processus pterygoidei*; (7) *ala minor*; (9) *canalis pterygoideus*; (11) *fissura orbitalis superior*
- B. (1) *dorsum sellae*; (2) *ala minor*; (5) *fissura orbitalis superior*; (7) *incisura pterygoidea*; (9) *canalis pterygoideus*; (11) *lamina medialis processus pterygoidei*
- C. (1) *dorsum sellae*; (2) *ala minor*; (5) *lamina medialis processus pterygoidei*; (7) *incisura pterygoidea*; (9) *canalis pterygoideus*; (11) *fissura orbitalis superior*
- D. (1) *dorsum sellae*; (2) *ala minor*; (5) *lamina medialis processus pterygoidei*; (7) *canalis pterygoideus*; (9) *incisura pterygoidea*; (11) *fissura orbitalis superior*
- E. (1) *dorsum sellae*; (2) *fissura orbitalis superior*; (5) *lamina medialis processus pterygoidei*; (7) *incisura pterygoidea*; (9) *canalis pterygoideus*; (11) *ala minor*.



Skica 5

9. Pravilna legenda **skice 5** je:
- A. (3) *ala major*; (4) *lamina lateralis processus pterygoidei*; (5) *lamina medialis processus pterygoidei*; (6) *hamulus pterygoideus*; (8) *processus vaginalis*; (10) *fossa scaphoidea*
- B. (3) *ala major*; (4) *processus vaginalis*; (5) *lamina medialis processus pterygoidei*; (6) *hamulus pterygoideus*; (8) *lamina lateralis processus pterygoidei*; (10) *fossa scaphoidea*

Skica 6

11. Pravilna legenda **skice 6** je:

- A. lobanja novorojenčka; mečave – od spodaj (*fonticuli cranii*), (1) *fonticulus anterior*; (2) *fonticulus posterior*; (3) *os frontale*; (4) *os parietale*; (5) *os occipitale*
- B. lobanja novorojenčka; mečave – od zgoraj (*fonticuli cranii*), (1) *fonticulus posterior*; (2) *fonticulus anterior*; (3) *os frontale*; (4) *os parietale*; (5) *os occipitale*
- C. lobanja novorojenčka; mečave – od zgoraj (*fonticuli cranii*), (1) *fonticulus anterior*; (2) *fonticulus posterior*; (3) *os occipitale*; (4) *os parietale*; (5) *os frontale*
- D. lobanja novorojenčka; mečave – od zgoraj (*fonticuli cranii*), (1) *fonticulus anterior*; (2) *fonticulus posterior*; (3) *os frontale*; (4) *os parietale*; (5) *os occipitale*
- E. lobanja novorojenčka; mečave – od zgoraj (*fonticuli cranii*), (1) *fonticulus anterior*; (2) *fonticulus posterior*; (3) *os frontale*; (4) *os occipitale*; (5) *os parietale*.

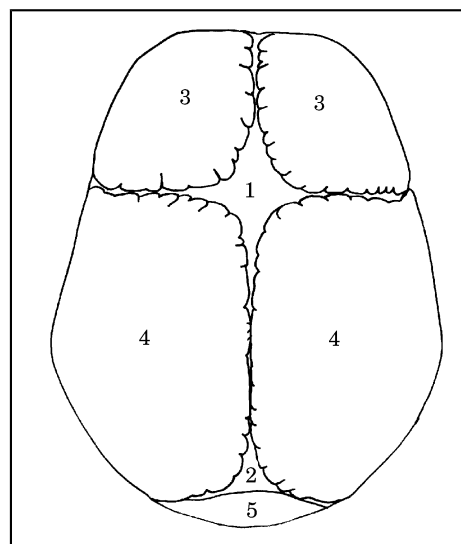
12. Pravilna legenda **skice 7** je:

- A. spodnja čeljustnica – z leve strani (*mandibula*), (1) *caput mandibulae*; (4) *ramus mandibulae*; (8) *corpus mandibulae*; (13) *canalis mandibulae*; (15) *processus condylaris*
- B. spodnja čeljustnica – z leve strani (*mandibula*), (1) *caput mandibulae*; (4) *processus condylaris*; (8) *corpus mandibulae*; (13) *canalis mandibulae*; (15) *ramus mandibulae*
- C. spodnja čeljustnica – z leve strani (*mandibula*), (1) *caput mandibulae*; (4) *ramus mandibulae*; (8) *canalis mandibulae*; (13) *corpus mandibulae*; (15) *processus condylaris*
- D. spodnja čeljustnica – z leve strani (*mandibula*), (1) *ramus mandibulae*; (4) *caput mandibulae*; (8) *corpus mandibulae*; (13) *canalis mandibulae*; (15) *processus condylaris*
- E. spodnja čeljustnica – z leve strani (*mandibula*), (1) *caput mandibulae*; (4) *ramus mandibulae*; (8) *corpus mandibulae*; (13) *processus condylaris*; (15) *canalis mandibulae*.

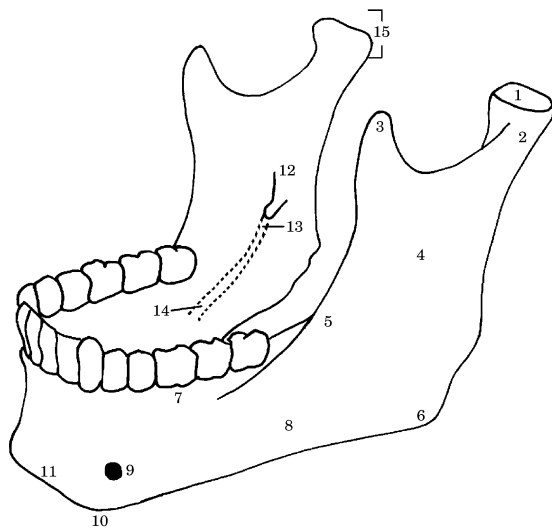
13. Pravilna legenda **skice 7** je:

- A. spodnja čeljustnica – z leve strani (*mandibula*), (2) *collum mandibulae*; (7) *pars alveolaris*; (9) *foramen mentale*; (11) *sulcus mylohyoideus*; (14) *protuberantia mentale*

- B. spodnja čeljustnica – z leve strani (*mandibula*), (2) *pars alveolaris*; (7) *collum mandibulae*; (9) *foramen mentale*; (11) *protuberantia mentale*; (14) *sulcus mylohyoideus*
- C. spodnja čeljustnica – z leve strani (*mandibula*), (2) *collum mandibulae*; (7) *sulcus mylohyoideus*; (9) *foramen mentale*; (11) *protuberantia mentale*; (14) *pars alveolaris*;
- D. zgornja čeljustnica – z leve strani (*mandibula*), (2) *collum mandibulae*; (7) *pars alveolaris*; (11) *foramen mentale*; (9) *protuberantia mentale*; (14) *sulcus mylohyoideus*
- E. spodnja čeljustnica – z leve strani (*mandibula*), (2) *collum mandibulae*; (7) *pars alveolaris*; (9) *foramen mentale*; (11) *protuberantia mentale*;



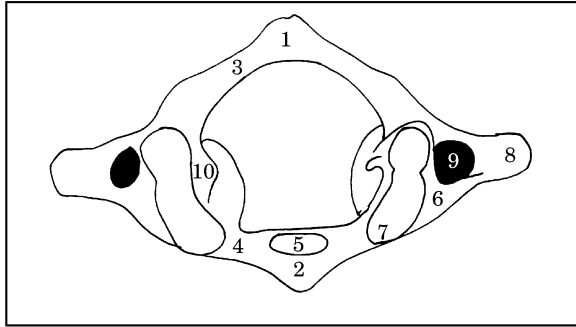
(14) *sulcus mylohyoideus*.



Skica 7

14. Pravilna legenda skice 7 je:

- A. spodnja čeljustnica – z leve strani (mandibula), (3) *processus coronoideus*; (5) *linea obliqua*; (6) *angulus mandibulae*; (10) *tuberculum mentale*; (12) *foramen mandibulae*
- B. zgornja čeljustnica – z leve strani (mandibula), (3) *linea obliqua*; (5) *processus coronoideus*; (6) *angulus mandibulae*; (10) *tuberculum mentale*; (12) *foramen mandibulae*
- C. spodnja čeljustnica – z leve strani (mandibula), (3) *processus coronoideus*; (5) *angulus mandibulae*; (6) *linea obliqua*; (10) *foramen mandibulae*; (12) *tuberculum mentale*
- D. spodnja čeljustnica – z leve strani (mandibula), (3) *foramen mandibulae*; (5) *linea obliqua*; (6) *angulus mandibulae*; (10) *tuberculum mentale*; (12) *processus coronoideus*
- E. spodnja čeljustnica – z leve strani (mandibula), (3) *tuberculum mentale*; (5) *linea obliqua*; (6) *angulus mandibulae*; (10) *processus coronoideus*; (12) *foramen mandibulae*.



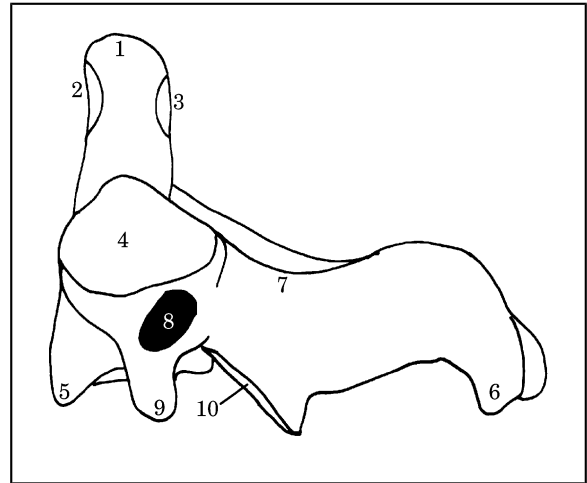
Skica 8

15. Pravilna legenda **skice 8** je:

- A. nosač – od zgoraj (*atlas*), (1) *tuberculum posterius*; (3) *processus transversus*; (5) *fovea dentis*; (8) *arcus posterior*; (10) *sulcus arteriae vertebralis*
- B. nosač – od zgoraj (*atlas*), (1) *tuberculum posterius*; (3) *arcus posterior*; (5) *fovea dentis*; (8) *processus transversus*; (10) *sulcus arteriae vertebralis*
- C. nosač – od zgoraj (*atlas*), (1) *tuberculum posterius*; (3) *arcus posterior*; (5) *sulcus arteriae vertebralis*; (8) *processus transversus*; (10) *fovea dentis*
- D. nosač – od zgoraj (*atlas*), (1) *fovea dentis*; (3) *arcus posterior*; (5) *tuberculum posterius*; (8) *processus transversus*; (10) *sulcus arteriae vertebralis*
- E. nosač – od spodaj (*atlas*), (1) *tuberculum posterius*; (3) *arcus posterior*; (5) *fovea dentis*; (8) *processus transversus*; (10) *sulcus arteriae vertebralis*.

16. Pravilna legenda **skice 8** je:

- A. nosač – od spodaj (*atlas*), (2) *tuberculum anterius*; (4) *arcus anterior*; (6) *massa lateralis*; (7) *fovea articularis superior*; (8) *processus transversus*; (9) *foramen transversarium*
- B. nosač – od zgoraj (*atlas*), (2) *foramen transversarium*; (4) *arcus anterior*; (6) *massa lateralis*; (7) *fovea articularis superior*; (8) *processus transversus*; (9) *tuberculum anterius*
- C. nosač – od zgoraj (*atlas*), (2) *tuberculum anterius*; (4) *arcus anterior*; (6) *processus transversus*; (7) *fovea articularis superior*; (8) *massa lateralis*; (9) *foramen transversarium*
- D. nosač – od zgoraj (*atlas*), (2) *tuberculum anterius*; (4) *arcus anterior*; (6) *massa lateralis*; (7) *foramen transversarium*; (8) *processus transversus*; (9) *fovea articularis superior*



- E. nosač – od zgoraj (*atlas*), (2) *tuberculum anterius*; (4) *arcus anterior*; (6) *massa lateralis*; (7) *fovea articularis superior*; (8) *processus transversus*; (9) *foramen transversarium*.

Skica 9

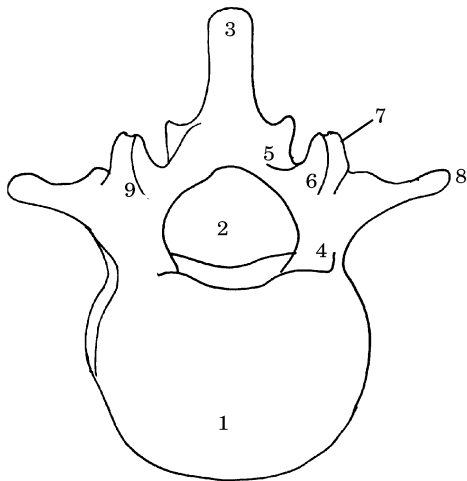
17. Pravilna legenda **skice 9** je:

- A. okretač – z leve strani (*axis*), (2) *facies articularis anterior*; (4) *processus articularis superior*; (6) *processus spinosus*; (7) *arcus*; (9) *processus transversus*
- B. okretač – z leve strani, (2) *facies articularis anterior*; (4) *processus articularis superior*; (6) *processus transversus*; (7) *arcus*; (9) *processus spinosus*
- C. okretač – z leve strani, (2) *processus articularis superior*; (4) *facies articularis anterior*; (6) *processus spinosus*; (7) *arcus*; (9) *processus transversus*
- D. okretač – z leve strani, (2) *facies articularis anterior*; (4) *arcus*; (6) *processus spinosus*; (7) *processus articularis superior*; (9) *processus transversus*
- E. okretač – z leve strani, (2) *facies articularis anterior*; (4) *processus articularis superior*; (6) *arcus*; (7) *processus spinosus*; (9) *processus transversus*.

18. Pravilna legenda **skice 9** je:

- A. okretač – z leve strani, (1) *corpus*; (3) *facies articularis posterior*; (5) *dens*; (8) *foramen transversarium*; (10) *processus articularis inferior*
- B. okretač – z leve strani (*axis*), (1) *dens*; (3) *facies articularis posterior*; (5) *corpus*; (8) *foramen*

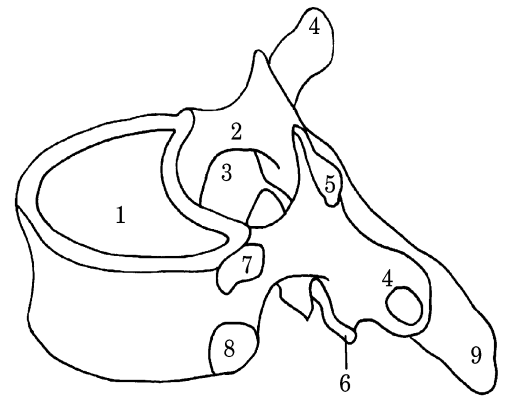
- transversarium*; (10) *processus articularis inferior*
- C. okretač – z leve strani, (1) *dens*; (3) *facies articularis posterior*; (5) *foramen transversarium*; (8) *corpus*; (10) *processus articularis inferior*
- D. okretač – z leve strani, (1) *dens*; (3) *processus articularis inferior*; (5) *corpus*; (8) *foramen transversarium*; (10) *facies articularis posterior*
- E. okretač – z leve strani, (1) *foramen transversarium*; (3) *facies articularis posterior*; (5) *corpus*; (8) *dens*; (10) *processus articularis inferior*.



Skica 10

19. Pravilna legenda **skice 10** je:
- A. prsno vretence, (3) *processus spinosus*; (4) *pediculus*; (5) *lamina*; (6) *processus articularis superior*; (9) *arcus*
- B. ledveno vretence, (3) *processus articularis superior*; (4) *pediculus*; (5) *lamina*; (6) *processus spinosus*; (9) *arcus*
- C. ledveno vretence, (3) *processus spinosus*; (4) *lamina*; (5) *pediculus*; (6) *processus articularis superior*; (9) *arcus*
- D. ledveno vretence, (3) *processus spinosus*; (4) *arcus*; (5) *lamina*; (6) *processus articularis superior*; (9) *pediculus*
- E. ledveno vretence, (3) *processus spinosus*; (4) *pediculus*; (5) *lamina*; (6) *processus articularis superior*; (9) *arcus*.

20. Pravilna legenda **skice 10** je:



- A. ledveno

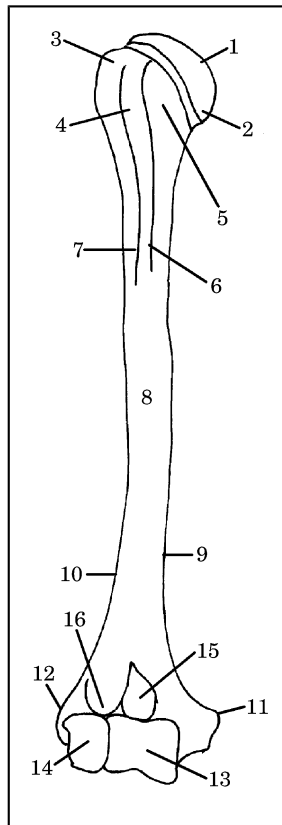
- vretence, (1) *corpus*; (2) *foramen vertebrale*; (6) *processus mammillaris*; (7) *processus transversus*; (8) *processus articularis superior*
- B. ledveno vretence, (1) *corpus*; (2) *foramen vertebrale*; (6) *processus articularis superior*; (7) *processus transversus*; (8) *processus mammillaris*
- C. prsno vretence, (1) *corpus*; (2) *foramen vertebrale*; (6) *processus articularis superior*; (7) *processus mammillaris*; (8) *processus transversus*
- D. ledveno vretence, (1) *processus transversus*; (2) *foramen vertebrale*; (6) *processus articularis superior*; (7) *processus mammillaris*; (8) *corpus*
- E. ledveno vretence, (1) *corpus*; (2) *foramen vertebrale*; (6) *processus articularis superior*; (7) *processus mammillaris*; (8) *processus transversus*.

Skica 11

21. Pravilna legenda **skice 11** je:
- A. ledveno vretence, (1) *corpus*; (3) *foramen vertebrale*; (5) *processus articularis superior*; (7) *fovea costalis superior*
- B. prsno vretence, (1) *foramen vertebrale*; (3) *corpus*; (5) *processus articularis superior*; (7) *fovea costalis superior*
- C. prsno vretence, (1) *corpus*; (3) *foramen vertebrale*; (5) *processus articularis superior*; (7) *fovea costalis superior*
- D. prsno vretence, (1) *corpus*; (3) *processus articularis superior*; (5) *foramen vertebrale*; (7) *fovea costalis superior*
- E. prsno vretence, (1) *corpus*; (3) *fovea costalis superior*; (5) *processus articularis superior*; (7) *foramen vertebrale*.
22. Pravilna legenda **skice 11** je:
- A. prsno vretence, (2) *pediculus*; (4) *processus transversus*; (6) *processus articularis inferior*;

- (8) *fovea costalis inferior*; (9) *processus spinosus*
- B. prsno vretence, (2) *pediculus*; (4) *processus spinosus* (6) *processus articularis inferior*; (8) *fovea costalis inferior*; (9) *processus transversus*
- C. ledveno vretence, (2) *pediculus*; (4) *processus transversus*; (6) *processus articularis inferior*; (8) *fovea costalis inferior*; (9) *processus spinosus*
- D. prsno vretence, (2) *pediculus*; (4) *processus articularis inferior*; (6) *processus transversus*; (8) *fovea costalis inferior*; (9) *processus spinosus*
- E. prsno vretence, (2) *processus transversus*; (4) *pediculus*; (6) *processus articularis inferior*; (8) *fovea costalis inferior*; (9) *processus spinosus*.

Skica 12



23. Pravilna legenda **skice 12** je:
- A. nadlahtnica – od spredaj, (1) *caput humeri*; (2) *collum anatomicum*; (6) *crista tuberculi minoris*; (11) *epicondylus lateralis*; (12) *epicondylus medialis*; (16) *fossa radialis*
- B. nadlahtnica – od zadaj, (1) *caput humeri*; (2) *collum anatomicum*; (6) *crista tuberculi*

- minoris*; (11) *epicondylus medialis*; (12) *epicondylus lateralis*; (16) *fossa radialis*
- C. nadlahtnica – od spredaj, (1) *caput humeri*; (2) *crista tuberculi minoris*; (6) *collum anatomicum*; (11) *epicondylus medialis*; (12) *epicondylus lateralis*; (16) *fossa radialis*
- D. nadlahtnica – od spredaj, (1) *caput humeri*; (2) *collum anatomicum*; (6) *crista tuberculi minoris*; (11) *epicondylus medialis*; (12) *epicondylus lateralis*; (16) *fossa radialis*
- E. nadlahtnica – od zadaj, (1) *collum anatomicum*; (2) *caput humeri*; (6) *crista tuberculi minoris*; (11) *epicondylus medialis*; (12) *epicondylus lateralis*; (16) *fossa radialis*.

24. Pravilna legenda **skice 12** je:

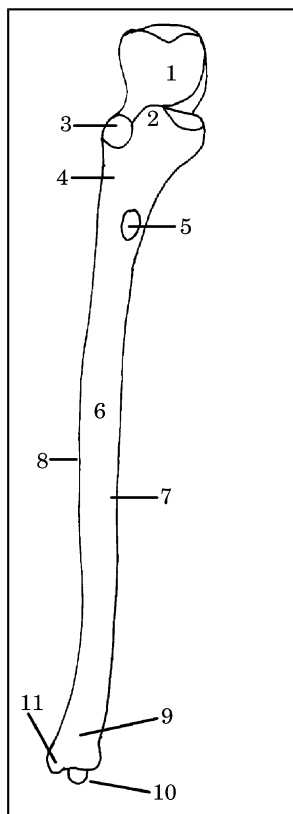
- A. nadlahtnica – od spredaj, (3) *tuberculum majus*; (5) *tuberculum minus*; (8) *corpus humeri*; (10) *margo lateralis*; (14) *capitulum humeri*
- B. nadlahtnica – od spredaj, (3) *tuberculum minus*; (5) *tuberculum majus*; (8) *corpus humeri*; (10) *margo lateralis*; (14) *capitulum humeri*
- C. nadlahtnica – od zadaj, (3) *tuberculum majus*; (5) *tuberculum minus*; (8) *corpus humeri*; (10) *capitulum humeri*; (14) *margo lateralis*
- D. nadlahtnica – od spredaj, (3) *tuberculum majus*; (5) *tuberculum minus*; (8) *capitulum humeri*; (10) *margo lateralis*; (14) *corpus humeri*
- E. nadlahtnica – od zadaj, (3) *tuberculum majus*; (5) *tuberculum minus*; (8) *corpus humeri*; (10) *margo lateralis*; (14) *capitulum humeri*.

25. Pravilna legenda **skice 12** je:

- A. nadlahtnica – od spredaj, (4) *crista tuberculi majoris*; (7) *sulcus intertubercularis*; (9) *margo medialis*; (13) *trochlea humeri*; (15) *fossa coronoidea*
- B. nadlahtnica – od spredaj, (3) *tuberculum majus*; (5) *tuberculum minus*; (8) *corpus humeri*; (10) *margo lateralis*; (14) *capitulum humeri*
- C. nadlahtnica – od zadaj, (4) *sulcus intertubercularis*; (7) *crista tuberculi majoris*; (9) *margo medialis*; (13) *trochlea humeri*; (15) *fossa coronoidea*
- D. nadlahtnica – od spredaj, (4) *fossa coronoidea*; (7) *crista tuberculi majoris*; (9) *margo medialis*; (13) *trochlea humeri*; (15) *sulcus intertubercularis*
- E. nadlahtnica – od zadaj, (4) *sulcus intertubercularis*; (7) *trochlea humeri*; (9) *margo medialis*; (13) *crista tuberculi majoris*; (15) *fossa coronoidea*.

26. Pravilna legenda **skice 13** je:

- A. leva podlahtnica – od spredaj, (1) *incisura trochlearis*; (3) *incisura radialis*; (4) *crista m. supinatoris*; (5) *tuberositas ulnae*; (8) *margo interosseus*; (10) *processus styloideus*
- B. desna podlahtnica – od spredaj, (1) *incisura radialis*; (3) *incisura trochlearis*; (4) *crista m. supinatoris*; (5) *tuberositas ulnae*; (8) *margo interosseus*; (10) *processus styloideus*
- C. desna podlahtnica – od spredaj, (1) *incisura trochlearis*; (3) *incisura radialis*; (4) *crista m. supinatoris*; (5) *tuberositas ulnae*; (8) *margo interosseus*; (10) *processus styloideus*
- D. desna podlahtnica – od spredaj, (1) *incisura radialis*; (3) *incisura trochlearis*; (4) *processus styloideus* (5) *crista m. supinatoris*; (8) *margo interosseus*; (10) *tuberositas ulnae*
- E. leva podlahtnica – od spredaj, (1) *incisura trochlearis*; (3) *incisura radialis*; (4) *crista m. supinatoris*; (5) *processus styloideus*; (8) *margo interosseus*; (10) *tuberositas ulnae*.



Skica 13

- B. desna podlahtnica – od spredaj, (2) *corpus ulnae*; (3) *incisura radialis*; (6) *processus coronoideus*; (7) *facies anterior*; (9) *caput ulnae*
- C. leva podlahtnica – od spredaj, (2) *processus coronoideus*; (3) *incisura radialis*; (6) *corpus ulnae*; (7) *facies anterior*; (9) *caput ulnae*
- D. leva podlahtnica – od spredaj, (2) *processus coronoideus*; (3) *incisura radialis*; (6) *corpus ulnae*; (7) *caput ulnae* (9) *facies anterior*
- E. desna podlahtnica – od spredaj, (2) *processus coronoideus*; (3) *incisura radialis*; (6) *caput ulnae*; (7) *facies anterior*; (9) *corpus ulnae*.

28. Pravilna legenda **skice 14** je:

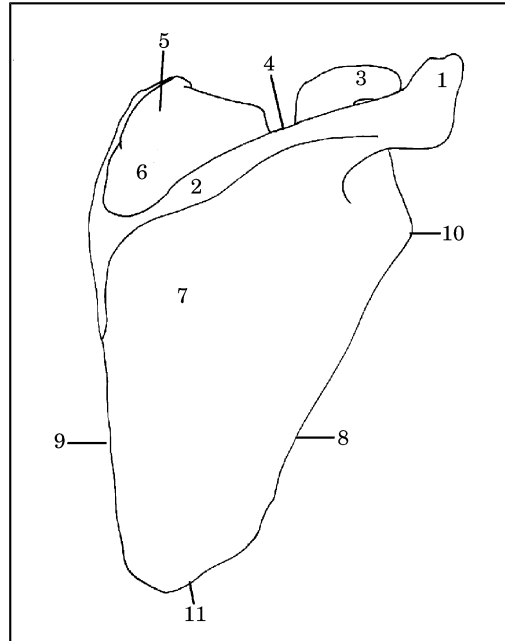
- A. lopatica – ventralna površina, (1) *acromion*; (3) *processus coracoideus*; (5) *angulus superior*; (7) *fossa infraspinata*; (11) *angulus lateralis*; (10) *angulus inferior*
- B. lopatica – dorzalna površina, (1) *acromion*; (3) *processus coracoideus*; (5) *angulus superior*; (7) *fossa infraspinata*; (10) *angulus lateralis*; (11) *angulus inferior*
- C. lopatica – dorzalna površina, (1) *acromion*; (3) *processus coracoideus*; (5) *angulus inferior*; (7) *fossa infraspinata*; (10) *angulus lateralis*; (11) *angulus superior*
- D. lopatica – dorzalna površina, (1) *acromion*; (3) *processus coracoideus*; (5) *angulus lateralis*; (7) *fossa infraspinata*; (10) *angulus superior*; (11) *angulus inferior*
- E. lopatica – dorzalna površina, (1) *processus coracoideus*; (3) *acromion*; (5) *angulus superior*; (7) *fossa infraspinata*; (10) *angulus lateralis*; (11) *angulus inferior*.

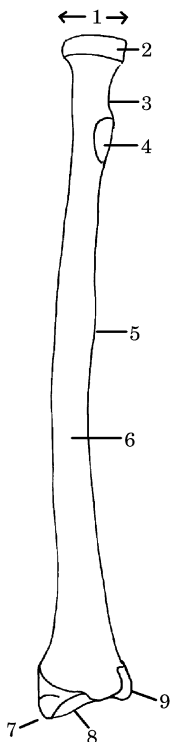
27. Pravilna legenda **skice 13** je:

- A. desna podlahtnica – od spredaj, (2) *processus coronoideus*; (3) *incisura radialis*; (6) *corpus ulnae*; (7) *facies anterior*; (9) *caput ulnae*

Skica 14

29. Pravilna legenda **skice 14** je:
- lopatica – dorzalna površina, (2) *spina scapulae*; (4) *incisura scapulae*; (6) *fossa supraspinata*; (8) *margo medialis*; (9) *margo lateralis*
 - lopatica – ventralna površina, (2) *margo medialis*; (4) *incisura scapulae*; (6) *fossa supraspinata*; (8) *margo lateralis*; (9) *spina scapulae*
 - lopatica – dorzalna površina, (2) *spina scapulae*; (4) *incisura scapulae*; (6) *fossa supraspinata*; (8) *margo lateralis*; (9) *margo medialis*
 - lopatica – dorzalna površina, (2) *incisura scapulae*; (4) *spina scapulae*; (6) *fossa supraspinata*; (8) *margo lateralis*; (9) *margo medialis*
 - lopatica – dorzalna površina, (2) *spina scapulae*; (4) *fossa supraspinata*; (8) *margo lateralis*; (9) *margo medialis*.





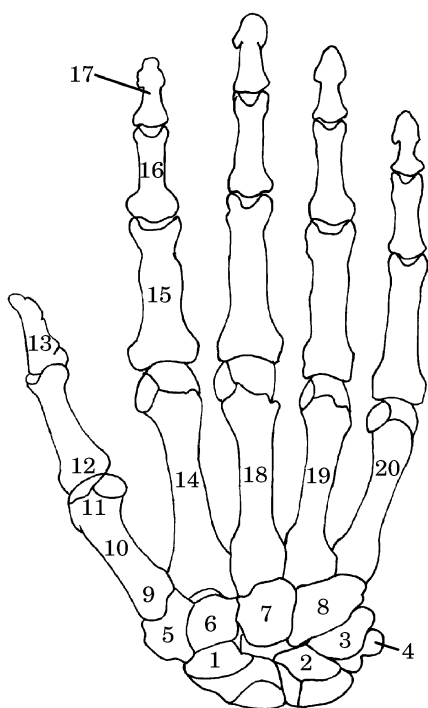
Skica 15

30. Pravilna legenda **skice 15** je:

- leva koželjnica – od spredaj, (2) *circumferentia articularis*; (4) *tuberositas radii*; (5) *margo interosseus*; (7) *processus styloideus*; (8) *facies articularis carpea*
- desna koželjnica – od spredaj, (2) *circumferentia articularis*; (4) *processus styloideus*; (5) *margo interosseus*; (7) *tuberositas radii*; (8) *facies articularis carpea*
- leva koželjnica – od spredaj, (2) *facies articularis carpea*; (4) *tuberositas radii*; (5) *margo interosseus*; (7) *processus styloideus*; (8) *circumferentia articularis*
- desna koželjnica – od spredaj, (2) *circumferentia articularis*; (4) *tuberositas radii*; (5) *processus styloideus*; (7) *margo interosseus*; (8) *facies articularis carpea*
- desna koželjnica – od spredaj, (2) *circumferentia articularis*; (4) *tuberositas radii*; (5) *margo interosseus*; (7) *processus styloideus*; (8) *facies articularis carpea*.

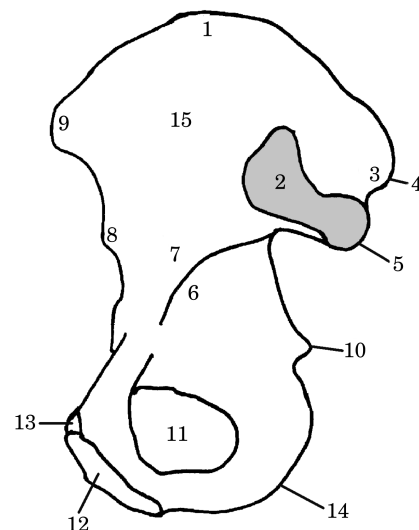
31. Pravilna legenda **skice 15** je:
- desna koželjnica – od spredaj, (1) *caput radii*; (3) *collum radii*; (6) *facies anterior*; (9) *incisura ulnaris*
 - leva koželjnica – od spredaj, (1) *caput radii*; (3) *collum radii*; (6) *facies anterior*; (9) *incisura ulnaris*
 - desna koželjnica – od spredaj, (1) *collum radii*; (3) *caput radii*; (6) *facies anterior*; (9) *incisura ulnaris*

- D. desna koželjnica – od spredaj, (1) *caput radii*; (3) *incisura ulnaris*; (6) *facies anterior*; (9) *collum radii*
- E. leva koželjnica – od spredaj, (1) *caput radii*; (3) *collum radii*; (6) *incisura ulnaris*; (9) *facies anterior*.



Skica 16

32. Pravilna legenda **skice 16** je:
- A. kosti leve roke – od zadaj, (1) *os scaphoideum*; (7) *os capitatum*; (11) *caput*; (16) *phalanx media*; (17) *phalanx distalis*
- B. kosti desne roke – od zadaj, (1) *os capitatum*; (7) *os scaphoideum*; (11) *caput*; (16) *phalanx media*; (17) *phalanx distalis*
- C. kosti desne roke – od zadaj, (1) *os scaphoideum*; (7) *os capitatum*; (11) *caput*; (16) *phalanx distalis*; (17) *phalanx media*
- D. kosti desne roke – od zadaj, (1) *os scaphoideum*; (7) *os capitatum*; (11) *caput*; (16) *phalanx media*; (17) *phalanx distalis*
- E. kosti desne roke – od zadaj, (1) *caput*; (7) *os capitatum*; (11) *os scaphoideum*; (16) *phalanx media*; (17) *phalanx distalis*.

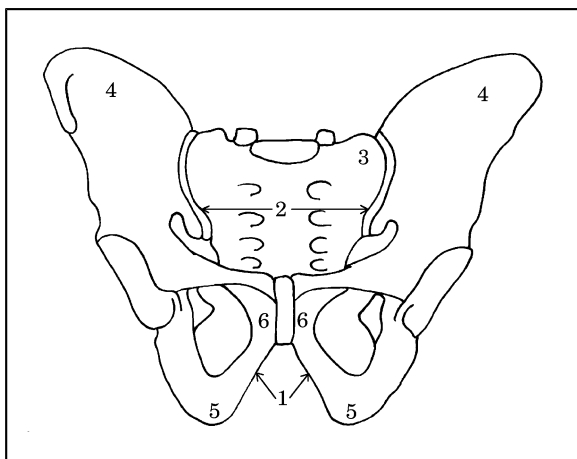


33. Pravilna legenda **skice 16** je:
- A. kosti leve roke – od zadaj, (2) *phalanx distalis pollicis*; (9) *basis*; (13) *os lunatum*; (19) *os metacarpale IV*; (20) *os metacarpale V*
- B. kosti leve roke – od zadaj, (2) *os lunatum*; (9) *basis*; (13) *phalanx distalis pollicis*; (19) *os metacarpale IV*; (20) *os metacarpale V*
- C. kosti desne roke – od zadaj, (2) *os lunatum*; (9) *basis*; (13) *phalanx distalis pollicis*; (19) *os metacarpale IV*; (20) *os metacarpale V*
- D. kosti desne roke – od zadaj, (2) *os metacarpale IV*; (9) *basis*; (13) *phalanx distalis pollicis*; (19) *os lunatum*; (20) *os metacarpale V*
- E. kosti desne roke – od zadaj, (2) *basis*; (9) *os lunatum*; (13) *phalanx distalis pollicis*; (19) *os metacarpale V*; (20) *os metacarpale IV*.
34. Pravilna legenda **skice 16** je:
- A. kosti desne roke – od zadaj, (3) *os triquetrum*; (6) *os hamatum*; (8) *os trapezoideum*; (14) *os metacarpale II*; (18) *os metacarpale III*
- B. kosti desne roke – od zadaj, (3) *os metacarpale II*; (6) *os trapezoideum*; (8) *os hamatum*; (14) *os triquetrum*; (18) *os metacarpale III*
- C. kosti desne roke – od zadaj, (3) *os triquetrum*; (6) *os trapezoideum*; (8) *os hamatum*; (14) *os metacarpale II*; (18) *os metacarpale III*
- D. kosti desne roke – od zadaj, (3) *os triquetrum*; (6) *os trapezoideum*; (8) *os hamatum*; (14) *os metacarpale III*; (18) *os metacarpale II*
- E. kosti leve roke – od zadaj, (3) *os triquetrum*; (6) *os trapezoideum*; (8) *os hamatum*; (14) *os metacarpale II*; (18) *os metacarpale III*.

35. Pravilna legenda **skice 16** je:
- A. kosti desne roke – od zadaj, (4) *os pisiforme*; (5) *os trapezium*; (10) *corpus*; (12) *phalanx proximalis pollicis*; (15) *phalanx proximalis*
 - B. kosti desne roke – od zadaj, (4) *os trapezium*; (5) *os pisiforme*; (10) *corpus*; (12) *phalanx proximalis pollicis*; (15) *phalanx proximalis*
 - C. kosti leve roke – od zadaj, (4) *os pisiforme*; (5) *os trapezium*; (10) *corpus*; (12) *phalanx proximalis pollicis*; (15) *phalanx proximalis*
 - D. kosti desne roke – od zadaj, (4) *os pisiforme*; (5) *os trapezium*; (10) *corpus*; (12) *phalanx proximalis*; (15) *phalanx proximalis pollicis*
 - E. kosti desne roke – od zadaj, (4) *corpus*; (5) *os trapezium*; (10) *os pisiforme*; (12) *phalanx proximalis pollicis*; (15) *phalanx proximalis*.
- ***
- C. desna kolčnica – medialna površina, (2) *facies auricularis*; (7) *corpus ossis ilii*; (9) *spina iliaca anterior superior*; (11) *tuber ischiadicum*; (14) *foramen obturatorium*
- D. desna kolčnica – medialna površina, (2) *facies auricularis*; (7) *tuber ischiadicum*; (9) *corpus ossis ilii*; (11) *foramen obturatorium*; (14) *spina iliaca anterior superior*
- E. desna kolčnica – lateralna površina, (2) *spina iliaca anterior superior*; (7) *corpus ossis ili*; (11) *foramen obturatorium*; (9) *tuber ischiadicum*; (14) *facies auricularis*.
38. Pravilna legenda **skice 17** je:

Skica 17

36. Pravilna legenda **skice 17** je:
- A. desna kolčnica – lateralna površina, (3) *tuberositas iliaca*; (5) *spina iliaca posterior inferior*; (6) *linea arcuata*; (10) *spina ischiadica*; (12) *crista pubica*
 - B. desna kolčnica – medialna površina, (3) *tuberositas iliaca*; (5) *spina iliaca posterior inferior*; (6) *linea arcuata*; (10) *spina ischiadica*; (12) *crista pubica*
 - C. desna kolčnica – medialna površina, (3) *tuberositas iliaca*; (5) *spina ischiadica*; (6) *linea arcuata*; (10) *spina iliaca posterior inferior*; (12) *crista pubica*
 - D. desna kolčnica – lateralna površina, (3) *crista pubica*; (5) *spina iliaca posterior inferior*; (6) *linea arcuata*; (10) *spina ischiadica*; (12) *tuberositas iliaca*
 - E. desna kolčnica – medialna površina, (3) *linea arcuata*; (5) *spina iliaca posterior inferior*; (6) *tuberositas iliaca*; (10) *spina ischiadica*; (12) *crista pubica*.
37. Pravilna legenda **skice 17** je:
- A. desna kolčnica – medialna površina, (2) *facies auricularis*; (7) *corpus ossis ilii*; (9) *spina iliaca anterior superior*; (11) *foramen obturatorium*; (14) *tuber ischiadicum*
 - B. desna kolčnica – lateralna površina, (2) *facies auricularis*; (7) *corpus ossis ilii*; (9) *spina iliaca anterior superior*; (11) *foramen obturatorium*; (14) *tuber ischiadicum*
- ***



Skica 18

39. Pravilna legenda skice 18 je:

- A. moška medenica, (1) *angulus subpubicus*; (2) *apertura pelvis superior*; (3) *os sacrum*; (4) *os ilium*; (5) *os ischii*; (6) *os pubis*
- B. ženska medenica, (1) *angulus subpubicus*; (2) *apertura pelvis superior*; (3) *os ilium*; (4) *os sacrum*; (5) *os ischii*; (6) *os pubis*
- C. moška medenica, (1) *angulus subpubicus*; (2) *apertura pelvis superior*; (3) *os sacrum*; (4) *os ilium*; (5) *os pubis*; (6) *os ischii*
- D. moška medenica, (1) *angulus subpubicus*; (2) *apertura pelvis superior*; (3) *os pubis*; (4) *os ilium*; (5) *os ischii*; (6) *os sacrum*
- E. ženska medenica, (1) *angulus subpubicus*; (2) *apertura pelvis superior*; (3) *os sacrum*; (4) *os ilium*; (5) *os ischii*; (6) *os pubis*.

Skica 19

40. Pravilna legenda skice 19 je:

- A. moška medenica, (1) *linea terminalis*; (2) *apertura pelvis superior*; (3) *arcus pubis*
- B. ženska medenica, (1) *arcus pubis*; (2) *apertura pelvis superior*; (3) *linea terminalis*
- C. ženska medenica, (1) *apertura pelvis superior*; (2) *linea terminalis*; (3) *arcus pubis*
- D. moška medenica, (1) *arcus pubis*; (2) *apertura pelvis superior*; (3) *linea terminalis*
- E. ženska medenica, (1) *linea terminalis*; (2) *apertura pelvis superior*; (3) *arcus pubis*.

41. Pravilna legenda skice 20 je:

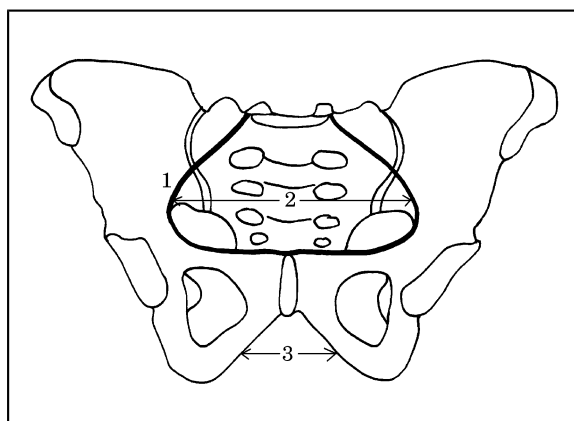
- A. desna petnica – medialna površina, (2) *facies articularis talaris anterior*; (3) *facies*

articularis talaris media; (4) *facies articularis cuboidea*; (6) *facies articularis talaris posterior*

- B. desna petnica – medialna površina, (2) *facies articularis talaris anterior*; (3) *facies articularis talaris media*; (4) *facies articularis talaris posterior*; (6) *facies articularis cuboidea*
- C. desna petnica – lateralna površina, (2) *facies articularis talaris anterior*; (3) *facies articularis talaris media*; (4) *facies articularis talaris posterior*; (6) *facies articularis cuboidea*
- D. desna petnica – medialna površina, (2) *facies articularis talaris media*; (3) *facies articularis talaris anterior*; (4) *facies articularis talaris posterior*; (6) *facies articularis cuboidea*
- E. desna petnica – lateralna površina, (2) *facies articularis cuboidea*; (3) *facies articularis talaris media*; (4) *facies articularis talaris posterior*; (6) *facies articularis talaris anterior*.

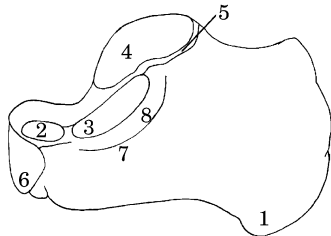
42. Pravilna legenda skice 20 je:

- A. desna petnica – medialna površina, (1) *tuber calcanei*; (5) *sulcus calcanei*; (7) *sustentaculum tali*; (8) *sulcus tendinis m. flexoris hallucis longi*
- B. desna petnica – medialna površina, (1) *tuber calcanei*; (5) *sulcus calcanei*; (7) *sulcus tendinis m. flexoris hallucis longi*; (8) *sustentaculum tali*
- C. desna petnica – medialna površina, (1) *sulcus calcanei*; (5) *tuber calcanei*; (7) *sustentaculum tali*; (8) *sulcus tendinis m. flexoris hallucis longi*



- D. desna petnica – lateralna površina, (1) *tuber calcanei*; (5) *sulcus calcanei*; (7) *sustentaculum tali*; (8) *sulcus tendinis m. flexoris hallucis longi*

- E. desna petnica – lateralna površina, (1) *sulcus tendinis m. flexoris hallucis longi*; (5) *sulcus calcanei*; (7) *sustentaculum tali*; (8) *tuber calcanei*.



Skica 20

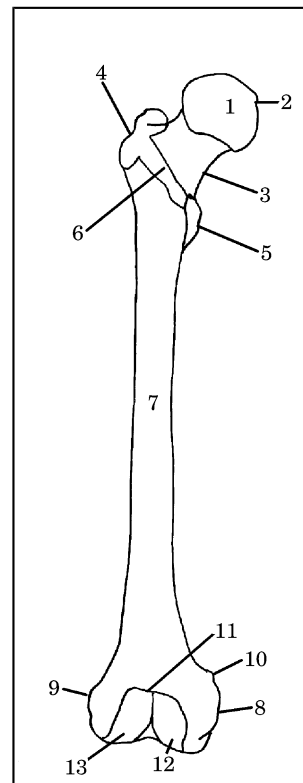
43. Pravilna legenda skice 21 je:

- A. desna stegnenica – od spredaj, (1) *caput femoris*; (4) *trochanter major*; (5) *trochanter minor*; (8) *epicondylus medialis*; (9) *epicondylus lateralis*
 B. leva stegnenica – od spredaj, (1) *caput femoris*; (4) *trochanter major*; (5) *trochanter minor*; (8) *epicondylus medialis*; (9) *epicondylus lateralis*
 C. desna stegnenica – od spredaj, (1) *caput femoris*; (4) *trochanter minor*; (5) *trochanter major*; (8) *epicondylus medialis*; (9) *epicondylus lateralis*
 D. desna stegnenica – od spredaj, (1) *caput femoris*; (4) *trochanter major*; (5) *trochanter minor*; (8) *epicondylus lateralis*; (9) *epicondylus medialis*
 E. leva stegnenica – od spredaj, (1) *caput femoris*; (4) *epicondylus lateralis*; (5) *trochanter minor*; (8) *epicondylus medialis*; (9) *trochanter major*.

Skica 21

44. Pravilna legenda skice 21 je:

- A. leva stegnenica – od spredaj, (2) *fovea capitis femoris*; (3) *linea intertrochanterica*; (6) *collum femoris*; (10) *tuberculum adductorium*
 B. desna stegnenica – od spredaj, (2) *tuberculum adductorium*; (3) *collum femoris*; (6) *linea intertrochanterica*; (10) *fovea capitis femoris*; (10) *tuberculum adductorium*
 C. desna stegnenica – od spredaj, (2) *linea intertrochanterica*; (3) *collum femoris*; (6) *fovea capitis femoris*; (10) *tuberculum adductorium*



- D. desna stegnenica – od spredaj, (2) *fovea capitis femoris*; (3) *collum femoris*; (6) *linea intertrochanterica*; (10) *tuberculum adductorium*
 E. leva stegnenica – od spredaj, (2) *fovea capitis femoris*; (3) *collum femoris*; (6) *linea intertrochanterica*; (10) *tuberculum adductorium*.

45. Pravilna legenda skice 21 je:

- A. leva stegnenica – od spredaj, (7) *corpus femoris*; (11) *facies patellaris*; (12) *condylus medialis*; (13) *condylus lateralis*
 B. desna stegnenica – od spredaj, (7) *corpus femoris*; (11) *facies patellaris*; (12) *condylus medialis*; (13) *condylus lateralis*
 C. leva stegnenica – od spredaj, (7) *corpus femoris*; (11) *facies patellaris*; (12) *condylus lateralis*; (13) *condylus medialis*
 D. desna stegnenica – od spredaj, (7) *facies patellaris*; (11) *corpus femoris*; (12) *condylus medialis*; (13) *condylus lateralis*
 E. desna stegnenica – od spredaj, (7) *condylus lateralis*; (11) *facies patellaris*; (12) *condylus medialis*; (13) *corpus femoris*.

46. Pravilna legenda skice 22 je:

- A. leva stegnenica – od zadaj, (4) *trochanter minor*; (5) *trochanter major*; (6) *linea*

- intertrochanterica*; (10) *linea supracondylaris lateralis*; (11) *linea supracondylaris medialis*
- B. desna stegnenica – od zadaj, (4) *trochanter minor*; (5) *trochanter major*; (6) *linea intertrochanterica*; (10) *linea supracondylaris lateralis*; (11) *linea supracondylaris medialis*
- C. desna stegnenica – od zadaj, (4) *trochanter major*; (5) *trochanter minor*; (6) *linea intertrochanterica*; (10) *linea supracondylaris lateralis*; (11) *linea supracondylaris medialis*
- D. leva stegnenica – od zadaj, (4) *trochanter minor*; (5) *trochanter major*; (6) *linea intertrochanterica*; (10) *linea supracondylaris medialis*; (11) *linea supracondylaris lateralis*
- E. desna stegnenica – od zadaj, (4) *trochanter minor*; (5) *trochanter major*; (6) *linea supracondylaris medialis*; (10) *linea supracondylaris lateralis*; (11) *linea intertrochanterica*.

- intercondylaris*; (17) *linea supracondylaris lateralis*
- D. desna stegnenica – od zadaj, (1) *caput femoris*; (2) *fovea capitis femoris*; (9) *facies poplitea*; (10) *linea supracondylaris lateralis*; (12) *epicondylus lateralis*; (13) *epicondylus medialis*; (16) *fossa intercondylaris*; (17) *linea intercondylaris*
- E. desna stegnenica – od zadaj, (1) *caput femoris*; (2) *fossa intercondylaris*; (9) *facies poplitea*; (10) *linea supracondylaris lateralis*; (12) *epicondylus lateralis*; (13) *epicondylus medialis*; (16) *fovea capitis femoris*; (17) *linea intercondylaris*.

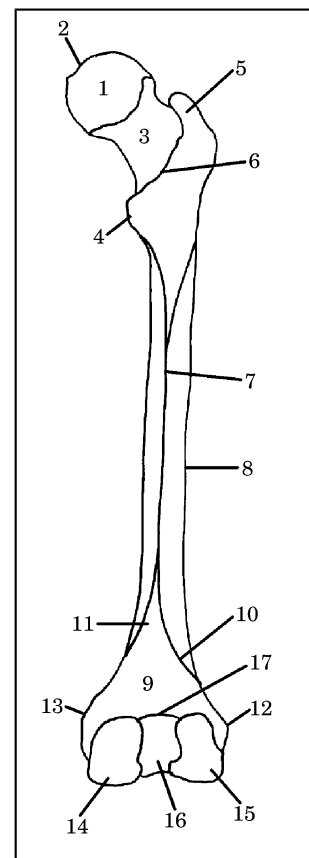
Skica 22

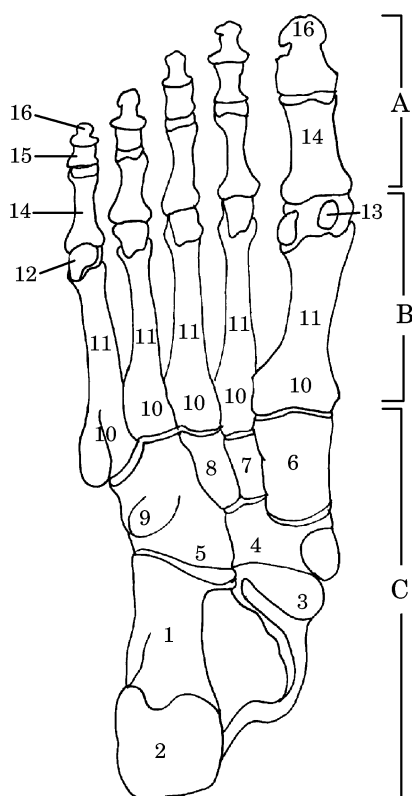
47. Pravilna legenda **skice 22** je:

- A. desna stegnenica – od zadaj, (3) *corpus femoris*; (7) *linea aspera*; (8) *collum femoris*; (14) *condylus medialis*; (15) *condylus lateralis*
- B. desna stegnenica – od zadaj, (3) *collum femoris*; (7) *linea aspera*; (8) *corpus femoris*; (14) *condylus medialis*; (15) *condylus lateralis*
- C. desna stegnenica – od zadaj, (3) *collum femoris*; (7) *linea aspera*; (8) *corpus femoris*; (14) *condylus lateralis*; (15) *condylus medialis*
- D. leva stegnenica – od zadaj, (3) *collum femoris*; (7) *linea aspera*; (8) *corpus femoris*; (14) *condylus medialis*; (15) *condylus lateralis*
- E. leva stegnenica – od zadaj, (3) *linea aspera*; (7) *collum femoris*; (8) *corpus femoris*; (14) *condylus medialis*; (15) *condylus lateralis*.

48. Pravilna legenda **skice 22** je:

- A. leva stegnenica – od zadaj, (1) *caput femoris*; (2) *fovea capitis femoris*; (9) *facies poplitea*; (10) *linea supracondylaris lateralis*; (12) *epicondylus lateralis*; (13) *epicondylus medialis*; (16) *fossa intercondylaris*; (17) *linea intercondylaris*
- B. leva stegnenica – od zadaj, (1) *caput femoris*; (2) *fovea capitis femoris*; (9) *facies poplitea*; (10) *linea supracondylaris lateralis*; (12) *epicondylus medialis*; (13) *epicondylus lateralis*; (16) *fossa intercondylaris*; (17) *linea intercondylaris*
- C. desna stegnenica – od zadaj, (1) *caput femoris*; (2) *fovea capitis femoris*; (9) *facies poplitea*; (12) *epicondylus lateralis*; (13) *epicondylus medialis*; (16) *fossa intercondylaris*; (10) *linea*





Skica 23

49. Pravilna legenda **skice 23** je:

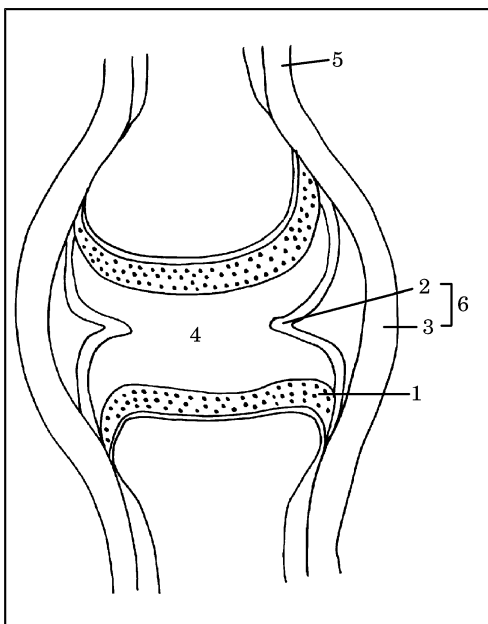
- A. kosti desnega stopala – od spodaj, (2) *tuber calcanei*; (9) *tuberositas ossis cuboidei*; (14) *phalanx proximalis*; (15) *phalanx media*; (16) *phalanx distalis*
- B. kosti desnega stopala – od zgoraj, (2) *tuber calcanei*; (9) *tuberositas ossis cuboidei*; (14) *phalanx proximalis*; (15) *phalanx media*; (16) *phalanx distalis*
- C. kosti desnega stopala – od spodaj, (2) *tuber calcanei*; (9) *tuberositas ossis cuboidei*; (14) *phalanx distalis*; (15) *phalanx media*; (16) *phalanx proximalis*
- D. kosti desnega stopala – od zgoraj, (2) *tuber calcanei*; (9) *tuberositas ossis cuboidei*; (14) *phalanx media*; (15) *phalanx proximalis*; (16) *phalanx distalis*
- E. kosti desnega stopala – od spodaj, (2) *tuberositas ossis cuboidei*; (9) *tuber calcanei*; (14) *phalanx proximalis*; (15) *phalanx media*; (16) *phalanx distalis*.

50. Pravilna legenda **skice 23** je:

- A. kosti desnega stopala – od zgoraj, **A.** *ossa digitorum pedis*; **B.** *metatarsus*; **C.** *tarsus*; (3) *caput tali*; (11) *corpus*; (12) *caput*
- B. kosti desnega stopala – od spodaj, **A.** *ossa digitorum pedis*; **B.** *tarsus*, **C.** *metatarsus*; (3) *caput tali*; (11) *corpus*; (12) *caput*
- C. kosti desnega stopala – od spodaj, **A.** *ossa digitorum pedis*; **B.** *metatarsus*; **C.** *tarsus*; (3) *caput*; (11) *corpus*; (12) *caput tali*
- D. kosti desnega stopala – od zgoraj, **A.** *metatarsus*; **B.** *ossa digitorum pedis*; **C.** *tarsus*, (3) *caput tali*; (11) *caput*; (12) *corpus*
- E. kosti desnega stopala – od spodaj, **A.** *ossa digitorum pedis*; **B.** *metatarsus*; **C.** *tarsus*; (3) *caput tali*; (11) *corpus*; (12) *caput*.

51. Pravilna legenda **skice 23** je:

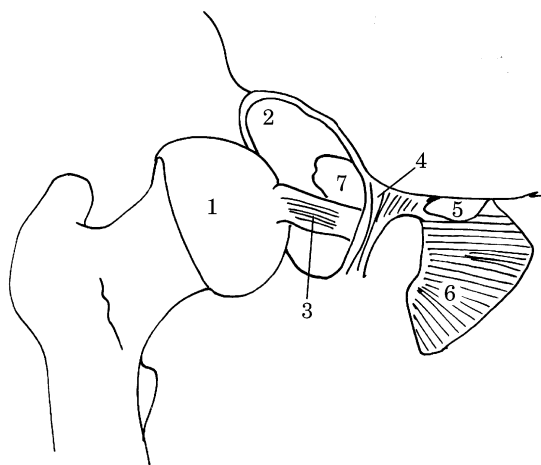
- A. kosti desnega stopala – od spodaj, (1) *calcaneus*; (3) *caput tali*; (4) *os naviculare*; (5) *os cuboideum*; (6) *os cuneiforme mediale*; (7) *os cuneiforme laterale*; (8) *os cuneiforme intermedium*; (10) *basis*; (13) *ossa sesamoidea*
- B. kosti desnega stopala – od zgoraj, (1) *calcaneus*; (3) *caput tali*; (4) *os naviculare*; (5) *os cuboideum*; (6) *os cuneiforme mediale*; (7) *os cuneiforme intermedium*; (8) *os cuneiforme laterale*; (10) *basis*; (13) *ossa sesamoidea*
- C. kosti desnega stopala – od spodaj, (1) *calcaneus*; (3) *caput tali*; (4) *os naviculare*; (5) *os cuboideum*; (6) *os cuneiforme mediale*; (7) *os cuneiforme intermedium*; (8) *os cuneiforme laterale*; (10) *basis*; (13) *ossa sesamoidea*
- D. kosti desnega stopala – od spodaj, (1) *calcaneus*; (3) *caput tali*; (4) *os naviculare*; (5) *os cuboideum*; (6) *os cuneiforme mediale*; (7) *ossa sesamoidea*; (8) *os cuneiforme laterale*; (10) *basis*; (13) *os cuneiforme intermedium*
- E. kosti desnega stopala – od spodaj, (1) *calcaneus*; (3) *caput tali*; (4) *os cuboideum*; (5) *os naviculare*; (6) *os cuneiforme mediale*; (7) *os cuneiforme intermedium*; (8) *os cuneiforme laterale*; (10) *basis*; (13) *ossa sesamoidea*.



Skica 24

52. Pravilna legenda **skice 24** je:

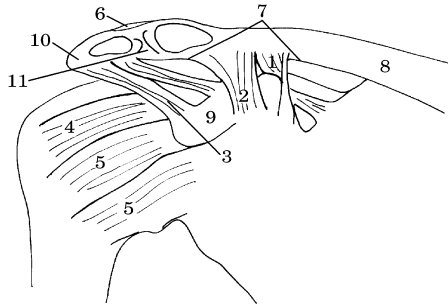
- A. pravi sklep – frontalni prerez, (1) *cartilago articularis*; (2) *membrana synovialis*; (3) *membrana fibrosa*; (4) *cavum articulare cum synovia*; (5) *periosteum*; (6) *capsula articularis*
- B. pravi sklep – frontalni prerez, (1) *cartilago articularis*; (2) *membrana fibrosa*; (3) *membrana synovialis*; (4) *cavum articulare cum synovia*; (5) *periosteum*; (6) *capsula articularis*
- C. pravi sklep – frontalni prerez, (1) *cartilago articularis*; (2) *membrana synovialis*; (3) *membrana fibrosa*; (4) *cavum articulare cum synovia*; (5) *capsula articularis*; (6) *periosteum*
- D. pravi sklep – frontalni prerez, (1) *capsula articularis*; (2) *membrana synovialis*; (3) *membrana fibrosa*; (4) *cavum articulare cum synovia*; (5) *periosteum*; (6) *cartilago articularis*
- E. nepravi sklep – frontalni prerez, (1) *cartilago articularis*; (2) *membrana synovialis*; (3) *membrana fibrosa*; (4) *cavum articulare cum synovia*; (5) *periosteum*; (6) *capsula articularis*.



Skica 25

53. Pravilna legenda **skice 25** je:

- A. odprti desni kolčni sklep – od spredaj, (1) *caput femoris*; (2) *acetabulum*; (3) *lig. capitis femoris*; (4) *lig. transversum acetabuli*; (5) *canalis obturatorius*; (6) *membrana obturatoria*; (7) *fossa acetabuli*
- B. odprti levi kolčni sklep – od spredaj, (1) *caput femoris*; (2) *acetabulum*; (3) *lig. capitis femoris*; (4) *lig. transversum acetabuli*; (5) *canalis obturatorius*; (6) *membrana obturatoria*; (7) *fossa acetabuli*
- C. odprti desni kolčni sklep – od spredaj, (1) *caput femoris*; (2) *acetabulum*; (3) *lig. transversum acetabuli*; (4) *lig. capitis femoris*; (5) *canalis obturatorius*; (6) *membrana obturatoria*; (7) *fossa acetabuli*
- D. odprti desni kolčni sklep – od spredaj, (1) *caput femoris*; (2) *acetabulum*; (3) *lig. capitis femoris*; (4) *lig. transversum acetabuli*; (5) *fossa acetabuli*; (6) *membrana obturatoria*; (7) *canalis obturatorius*
- E. odprti levi kolčni sklep – od spredaj, (1) *acetabulum*; (2) *caput femoris*; (3) *lig. capitis femoris*; (4) *lig. transversum acetabuli*; (5) *canalis obturatorius*; (6) *membrana obturatoria*; (7) *fossa acetabuli*.

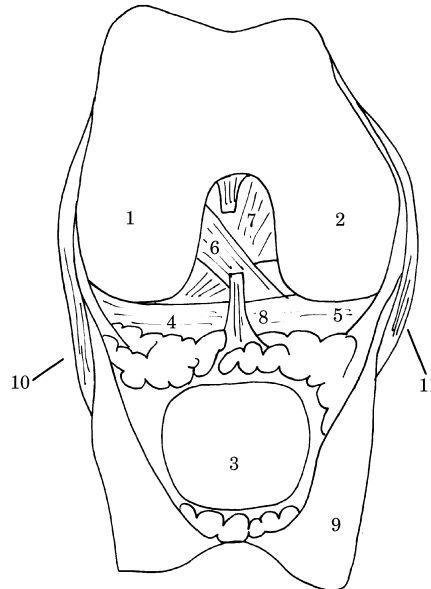


Skica 26

54. Pravilna legenda **skice 26** je:
- A. stranske ramenske vezi, (1) *ligg. glenohumeralia*; (3) *lig. coracoacromiale*; (5) *lig. conoideum*; (8) *clavicula*; (9) *processus coracoideus*
 - B. stranske ramenske vezi, (1) *lig. conoideum*; (3) *ligg. glenohumeralia*; (5) *lig. coracoacromiale*; (8) *clavicula*; (9) *processus coracoideus*
 - C. stranske ramenske vezi, (1) *lig. conoideum*; (3) *lig. coracoacromiale*; (5) *ligg. glenohumeralia*; (8) *clavicula*; (9) *processus coracoideus*
 - D. stranske ramenske vezi, (1) *lig. coracoacromiale*; (3) *lig. conoideum*; (5) *ligg. glenohumeralia*; (8) *clavicula*; (9) *processus coracoideus*
 - E. stranske ramenske vezi, (1) *lig. conoideum*; (3) *lig. coracoacromiale*; (5) *ligg. glenohumeralia*; (8) *processus coracoideus*; (9) *clavicula*.
55. Pravilna legenda **skice 26** je:
- A. stranske ramenske vezi, (2) *lig. trapezoideum*; (4) *lig. coracohumerale*; (6) *lig. acromioclaviculare*; (7) *lig. coracoclaviculare*; (8) *clavicula*; (10) *acromion*; (11) *discus articularis*
 - B. stranske ramenske vezi, (2) *lig. trapezoideum*; (4) *lig. acromioclaviculare*; (6) *lig. coracohumerale*; (7) *lig. coracoclaviculare*; (8) *clavicula*; (10) *acromion*; (11) *discus articularis*
 - C. stranske ramenske vezi, (2) *lig. acromioclaviculare*; (4) *lig. coracohumerale*; (6) *lig. trapezoideum*; (7) *lig.*

coracoclaviculare; (8) *clavicula*; (10) *acromion*; (11) *discus articularis*

- D. stranske ramenske vezi, (2) *lig. trapezoideum*; (4) *lig. coracoclaviculare*; (6) *lig. acromioclaviculare*; (7) *lig. coracohumerale*; (8) *clavicula*; (10) *acromion*; (11) *discus*



- articularis*
- E. stranske ramenske vezi, (2) *lig. trapezoideum*; (4) *lig. coracohumerale*; (6) *lig. coracoclaviculare*; (7) *lig. acromioclaviculare*; (8) *clavicula*; (10) *acromion*; (11) *discus articularis*.

Skica 27

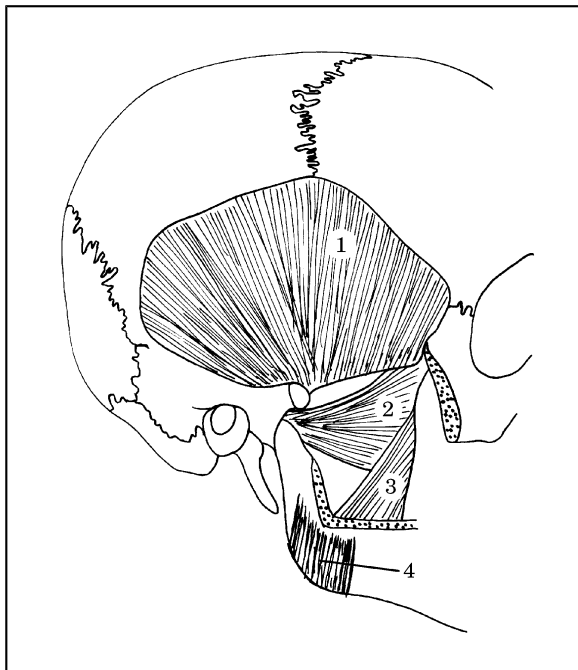
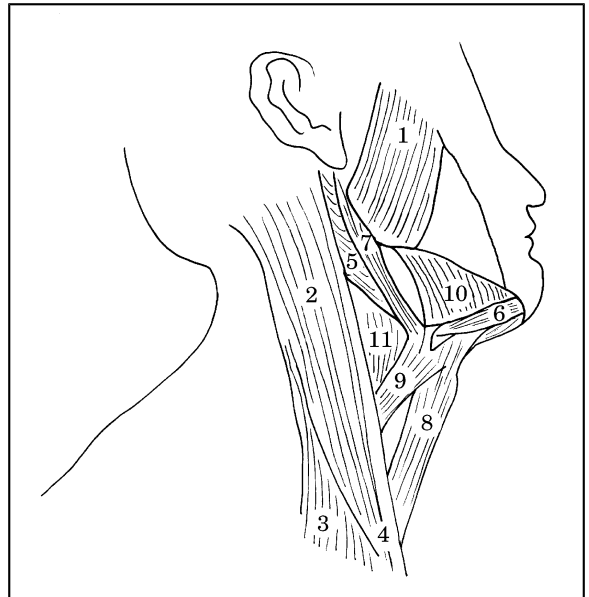
56. Pravilna legenda **skice 27** je:
- A. odprti desni kolenski sklep – od zadaj, (1) *condylus lateralis ossis femoris*; (2) *condylus medialis ossis femoris*; (4) *meniscus lateralis*; (5) *meniscus medialis*; (9) *capsula articularis*
 - B. odprti desni kolenski sklep – od spredaj, (1) *condylus lateralis ossis femoris*; (2) *condylus medialis ossis femoris*; (4) *meniscus medialis*; (5) *meniscus lateralis*; (9) *capsula articularis*
 - C. odprti desni kolenski sklep – od zadaj, (1) *condylus medialis ossis femoris*; (2) *condylus lateralis ossis femoris*; (4) *meniscus lateralis*; (5) *meniscus medialis*; (9) *capsula articularis*
 - D. odprti desni kolenski sklep – od spredaj, (1) *condylus lateralis ossis femoris*; (2) *condylus medialis ossis femoris*; (4) *meniscus lateralis*; (5) *meniscus medialis*; (9) *capsula articularis*

- E. odprti desni kolenski sklep – od spredaj, (1) *meniscus lateralis*; (2) *condylus medialis ossis femoris*; (4) *condylus lateralis ossis femoris*; (5) *meniscus medialis*; (9) *capsula articularis*.

Skica 28

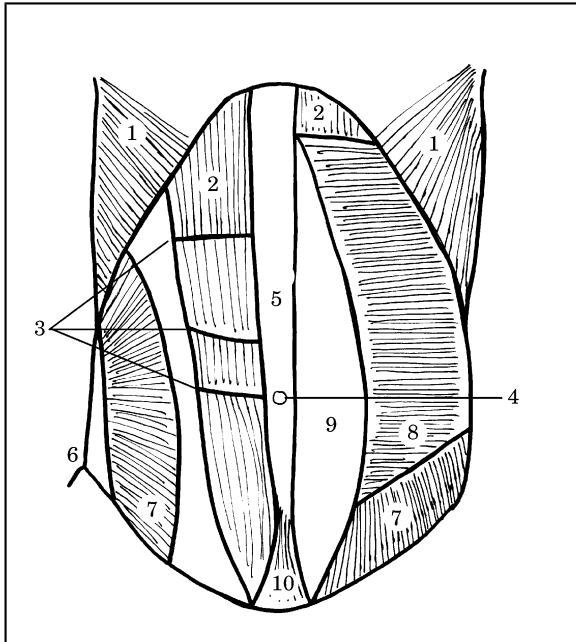
57. Pravilna legenda **skice 27** je:

- A. odprti desni kolenski sklep – od spredaj, (6) *lig. transversum genus*; (7) *lig. cruciatum posterius*; (8) *lig. cruciatum anterius*; (10) *lig. collaterale fibulare*; (11) *lig. collaterale tibiale*
- B. odprti desni kolenski sklep – od spredaj, (6) *lig. cruciatum anterius*; (7) *lig. cruciatum posterius*; (8) *lig. transversum genus*; (10) *lig. collaterale fibulare*; (11) *lig. collaterale tibiale*
- C. odprti desni kolenski sklep – od spredaj, (6) *lig. cruciatum anterius*; (7) *lig. collaterale tibiale*; (8) *lig. transversum genus*; (10) *lig. collaterale fibulare*; (11) *lig. cruciatum posterius*
- D. odprti desni kolenski sklep – od spredaj, (7) *lig. cruciatum posterius*; (8) *lig. transversum genus*; (6) *lig. collaterale fibulare*; (10) *lig. cruciatum anterius*; (11) *lig. collaterale tibiale*
- E. odprti desni kolenski sklep – od spredaj, (6) *lig. cruciatum anterius*; (7) *lig. cruciatum posterius*; (8) *lig. collaterale tibiale*; (10) *lig. collaterale fibulare*; (11) *lig. transversum genus*.



58. Pravilna legenda **skice 28** je:

- A. (1) *m. temporalis*; (2) *m. masseter*; (3) *m. pterygoideus medialis*; (4) *m. pterygoideus lateralis*
- B. (1) *m. temporalis*; (2) *m. pterygoideus medialis*; (3) *m. pterygoideus lateralis*; (4) *m. masseter*
- C. (1) *m. temporalis*; (2) *m. pterygoideus lateralis*; (3) *m. pterygoideus medialis*; (4) *m. masseter*
- D. (1) *m. masseter*; (2) *m. pterygoideus lateralis*; (3) *m. pterygoideus medialis*; (4) *m. temporalis*
- E. (1) *m. temporalis lateralis*; (2) *m. pterygoideus lateralis*; (3) *m. pterygoideus medialis*; (4) *m.*



masseter.

Skica 29

59. Pravilna legenda **skice 29** je:

- A. (1) *m. digastricus, venter posterior*; (3) *m. sternocleidomastoideus, caput claviculare*; (5) *m. masseter*; (7) *m. stylohyoideus*; (9) *m. omohyoideus*; (11) *m. thyrohyoideus*
- B. (1) *m. sternocleidomastoideus, caput claviculare*; (3) *m. masseter*; (5) *m. digastricus, venter posterior*; (7) *m. stylohyoideus*; (9) *m. omohyoideus*; (11) *m. thyrohyoideus*
- C. (1) *m. masseter*; (3) *m. sternocleidomastoideus, caput claviculare*; (5) *m. digastricus, venter posterior*; (7) *m.*

omohyoideus; (9) *m. stylohyoideus*; (11) *m. thyrohyoideus*

- D. (1) *m. masseter*; (3) *m. sternocleidomastoideus, caput claviculare*; (5) *m. digastricus, venter posterior*; (7) *m. stylohyoideus*; (9) *m. omohyoideus*; (11) *m. thyrohyoideus*
- E. (1) *m. masseter*; (3) *m. sternocleidomastoideus, caput claviculare*; (5) *m. omohyoideus*; (7) *m. stylohyoideus*; (9) *m. digastricus, venter posterior*; (11) *m. thyrohyoideus.*

60. Pravilna legenda **skice 29** je:

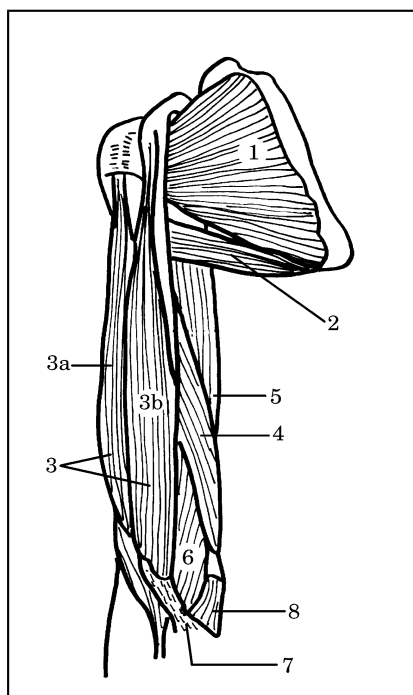
- A. (2) *m. sternocleidomastoideus*; (4) *m. digastricus venter anterior*; (6) *m. sternocleidomastoideus, caput sternale*; (8) *m. sternohyoideus*; (10) *m. mylohyoideus*
- B. (2) *m. sternocleidomastoideus*; (4) *m. sternohyoideus*; (6) *m. digastricus venter anterior*; (8) *m. sternocleidomastoideus, caput sternale*; (10) *m. mylohyoideus*
- C. (2) *m. sternocleidomastoideus*; (4) *m. sternocleidomastoideus, caput sternale*; (6) *m. digastricus venter anterior*; (8) *m. sternohyoideus*; (10) *m. mylohyoideus*
- D. (2) *m. mylohyoideus*; (4) *m. sternocleidomastoideus, caput sternale*; (6) *m. digastricus venter anterior*; (8) *m. sternohyoideus*; (10) *m. sternocleidomastoideus*
- E. (2) *m. sternocleidomastoideus*; (4) *m. mylohyoideus*; (6) *m. digastricus venter anterior*; (8) *m. sternohyoideus*; (10) *m. sternocleidomastoideus, caput sternale.*

Skica 30

61. Pravilna legenda **skice 30** je:

- A. (2) *m. pyramidalis*; (4) *anulus umbilicalis*; (6) *spina iliaca anterior superior*; (8) *m. transversus abdominis*; (10) *m. rectus abdominis*
- B. (2) *m. rectus abdominis*; (4) *m. transversus abdominis*; (6) *spina iliaca anterior superior*; (8) *anulus umbilicalis*; (10) *m. pyramidalis*
- C. (2) *m. rectus abdominis*; (4) *anulus umbilicalis*; (6) *spina iliaca anterior superior*; (8) *m. transversus abdominis*; (10) *m. pyramidalis*
- D. (2) *spina iliaca anterior superior*; (4) *anulus umbilicalis*; (6) *m. rectus abdominis*; (8) *m. transversus abdominis*; (10) *m. pyramidalis*

- E. (2) *m. rectus abdominis*; (4) *m. pyramidalis*; (6) *spina iliaca anterior superior*; (8) *m. transversus abdominis*; (10) *anulus umbilicalis*.



62. Pravilna legenda skice 30 je:

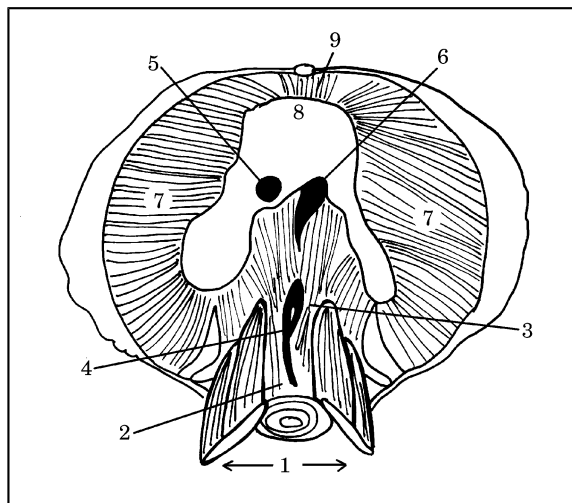
- A. (1) *intersecciones tendineae*; (3) *m. obliquus externus abdominis*; (5) *linea alba*; (7) *m. obliquus internus abdominis*; (9) *vagina m. recti abdominis*
 B. (1) *m. obliquus externus abdominis*; (3) *intersecciones tendineae*; (5) *linea alba*; (7) *vagina m. recti abdominis*; (9) *m. obliquus internus abdominis*
 C. (1) *m. obliquus externus abdominis*; (3) *intersecciones tendineae*; (5) *linea alba*; (7) *m. obliquus internus abdominis*; (9) *vagina m. recti abdominis*
 D. (1) *m. obliquus externus abdominis*; (3) *linea alba*; (5) *intersecciones tendineae*; (7) *m. obliquus internus abdominis*; (9) *vagina m. recti abdominis*
 E. (1) *vagina m. recti abdominis*; (3) *intersecciones tendineae*; (5) *linea alba*; (7) *m. obliquus internus abdominis*; (9) *m. obliquus externus abdominis*.

Skica 31

63. Pravilna legenda skice 31 je:

- A. trebušna prepona – od spodaj, (1) *pars lumbalis*; (2) *crus dextrum*; (3) *crus sinistrum*; (4) *hiatus aorticus*; (5) *foramen venae cavae*; (6) *hiatus esophageus*; (7) *pars costalis*; (8) *centrum tendineum*; (9) *pars sternalis*
 B. trebušna prepona – od zgoraj, (1) *pars lumbalis*; (2) *crus dextrum*; (3) *crus sinistrum*; (4) *hiatus aorticus*; (5) *foramen venae cavae*; (6) *hiatus esophageus*; (7) *pars costalis*; (8) *centrum tendineum*; (9) *pars sternalis*
 C. trebušna prepona – od spodaj, (1) *pars lumbalis*; (2) *crus dextrum*; (3) *crus sinistrum*; (4) *hiatus esophageus*; (5) *foramen venae cavae*; (6) *hiatus aorticus*; (7) *pars costalis*; (8) *centrum tendineum*; (9) *pars sternalis*
 D. trebušna prepona – od spodaj, (1) *pars lumbalis*; (2) *crus dextrum*; (3) *crus sinistrum*; (4) *hiatus aorticus*; (5) *foramen venae cavae*; (6) *hiatus esophageus*; (7) *pars sternalis*; (8) *centrum tendineum*; (9) *pars costalis*
 E. trebušna prepona – od zgoraj, (1) *pars lumbalis*; (2) *crus sinistrum*; (3) *crus dextrum*; (4) *hiatus aorticus*; (5) *foramen venae cavae*; (6) *hiatus esophageus*; (7) *pars costalis*; (8) *centrum tendineum*; (9) *pars sternalis*.

Skica 32



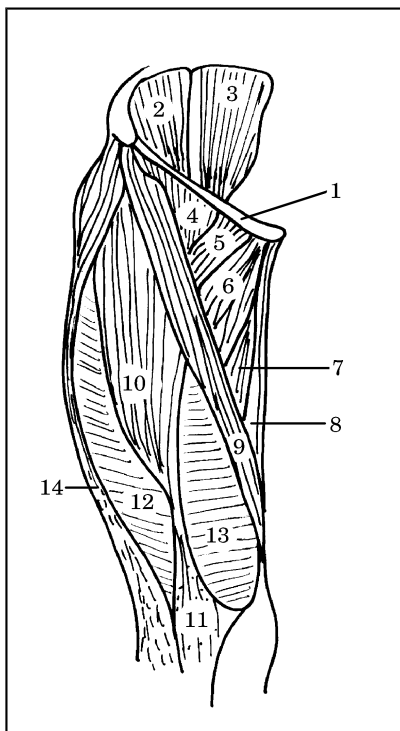
64. Pravilna legenda skice 32 je:

- A. desna nadlaket – od zadaj, (2) *m. teres major*; (4) *m. coracobrachialis*; (6) *m. brachialis*; (8) *m. pronator teres*
 B. desna nadlaket – od spredaj, (2) *m. coracobrachialis*; (4) *m. teres major*; (6) *m. brachialis*; (8) *m. pronator teres*

- C. desna nadlaket – od spredaj, (2) *m. teres major*; (4) *m. coracobrachialis*; (6) *m. brachialis*; (8) *m. pronator teres*
- D. desna nadlaket – od spredaj, (2) *m. brachialis*; (4) *m. coracobrachialis*; (6) *m. teres major*; (8) *m. pronator teres*
- E. desna nadlaket – od spredaj, (2) *m. teres major*; (4) *m. pronator teres*; (6) *m. brachialis*; (8) *m. coracobrachialis*.

65. Pravilna legenda **skice 32** je:

- A. desna nadlaket – od spredaj, (1) *m. subscapularis*; (3) *m. biceps brachii* (a) *caput breve*, (b) *caput longum*; (5) *m. triceps – caput longum*; (7) *aponeurosis m. bicipitis brachii*
- B. desna nadlaket – od zadaj, (1) *m. subscapularis*; (3) *m. biceps brachii* (a) *caput longum*, (b) *caput breve*; (5) *m. triceps – caput longum*; (7) *aponeurosis m. bicipitis brachii*
- C. desna nadlaket – od spredaj, (1) *m. subscapularis*; (3) *m. triceps – caput longum*; (5) *m. biceps brachii* (a) *caput longum*, (b) *caput breve*; (7) *aponeurosis m. bicipitis brachii*



- D. desna nadlaket – od spredaj, (1) *m. subscapularis*; (3) *m. biceps brachii* (a) *caput longum*, (b) *caput breve*; (5) *m. triceps – caput longum*; (7) *aponeurosis m. bicipitis brachii*
- E. desna nadlaket – od spredaj, (1) *aponeurosis m. bicipitis brachii*; (3) *m. biceps brachii*, (a)

caput longum, (b) *caput breve*; (5) *m. triceps – caput longum*; (7) *m. subscapularis*.

66. Pravilna legenda **skice 33** je:

- A. desno stegno – od spredaj (*regio femoralis anterior*), (1) *lig. patellae*; (3) *m. psoas*; (5) *m. pectineus*; (7) *m. adductor magnus*; (9) *m. sartorius*; (11) *lig. inguinale*
- B. desno stegno – od zadaj (*regio femoralis anterior*), (1) *lig. inguinale*; (3) *m. psoas*; (5) *m. pectineus*; (7) *m. adductor magnus*; (9) *m. sartorius*; (11) *lig. patellae*
- C. desno stegno – od spredaj (*regio femoralis anterior*), (1) *lig. inguinale*; (3) *m. psoas*; (5) *m. pectineus*; (7) *m. adductor magnus*; (9) *m. sartorius*; (11) *lig. patellae*
- D. desno stegno – od spredaj (*regio femoralis anterior*), (1) *lig. inguinale*; (3) *m. psoas*; (5) *m. sartorius*; (7) *m. adductor magnus*; (9) *m. pectineus*; (11) *lig. patellae*
- E. desno stegno – od spredaj (*regio femoralis anterior*), (1) *lig. inguinale*; (3) *m. adductor magnus*; (5) *m. pectineus*; (7) *m. psoas*; (9) *m. sartorius*; (11) *lig. patellae*.

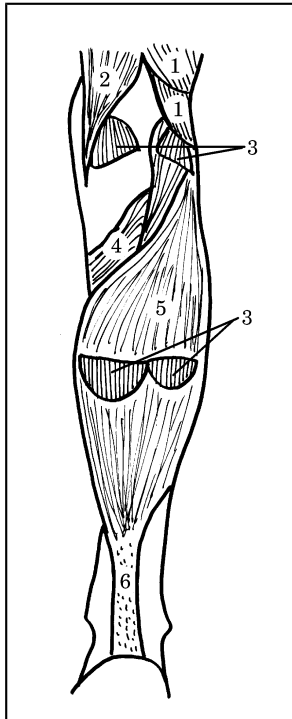
67. Pravilna legenda **skice 33** je:

- A. desno stegno – od spredaj (*regio femoralis anterior*), (2) *m. iliacus*; (4) *m. iliopsoas*; (6) *m. adductor longus*; (12) *m. vastus lateralis*; (14) *tractus iliotibialis*
- B. desno stegno – od spredaj (*regio femoralis anterior*), (2) *m. iliacus*; (4) *m. adductor longus*; (6) *m. iliopsoas*; (12) *m. vastus lateralis*; (14) *tractus iliotibialis*
- C. desno stegno – od spredaj (*regio femoralis anterior*), (2) *m. vastus lateralis*; (4) *m. iliopsoas*; (6) *m. adductor longus*; (12) *m. iliacus*; (14) *tractus iliotibialis*
- D. desno stegno – od spredaj (*regio femoralis anterior*), (2) *m. adductor longus*; (4) *m. iliopsoas*; (6) *m. iliacus*; (12) *m. vastus lateralis*; (14) *tractus iliotibialis*
- E. levo stegno – od spredaj (*regio femoralis anterior*), (2) *m. iliacus*; (4) *m. iliopsoas*; (6) *m. adductor longus*; (12) *m. vastus lateralis*; (14) *tractus iliotibialis*.

Skica 33

68. Pravilna legenda **skice 33** je:

- A. desno stegno – od spredaj (*regio femoralis anterior*), (7) *m. sartorius*; (8) *m. gracilis*; (9)



- m. adductor magnus*; (10) *m. rectus femoris*; (13) *m. vastus medialis*
- B. desno stegno – od spredaj (*regio femoralis anterior*), (7) *m. adductor magnus*; (8) *m. gracilis*; (9) *m. sartorius*; (10) *m. rectus femoris*; (13) *m. vastus medialis*
- C. desno stegno – od spredaj (*regio femoralis anterior*), (7) *m. vastus medialis*; (8) *m. gracilis*; (9) *m. sartorius*; (10) *m. rectus femoris*; (13) *m. adductor magnus*;
- D. desno stegno – od spredaj (*regio femoralis anterior*), (7) *m. adductor magnus*; (8) *m. sartorius*; (9) *m. gracilis*; (10) *m. rectus femoris*; (13) *m. vastus medialis*
- E. desno stegno – od spredaj (*regio femoralis anterior*), (7) *m. adductor magnus*; (8) *m. rectus femoris*; (9) *m. sartorius*; (10) *m. gracilis*; (13) *m. vastus medialis*.

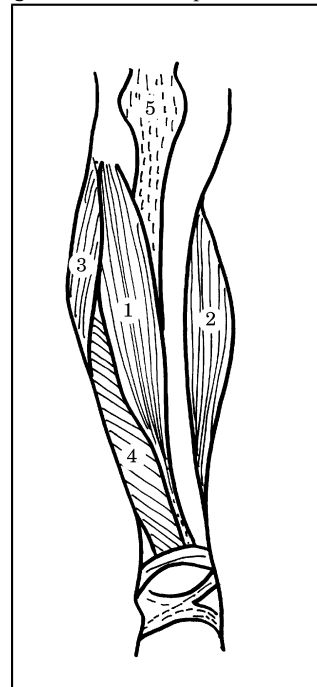
Skica 34

69. Pravilna legenda **skice 34** je:
- A. desna golen – od spredaj (*crus*), (1) *m. tibialis anterior*; (2) *m. gastrocnemius – caput mediale*; (3) *m. peroneus longus*; (4) *m. extensor digitorum longus*; (5) *lig. patellae*
- B. desna golen – od spredaj (*crus*), (1) *m. tibialis anterior*; (2) *lig. patellae*; (3) *m. peroneus longus*; (4) *m. extensor digitorum longus*; (5) *m. gastrocnemius – caput mediale*

- C. desna golen – od spredaj (*crus*), (1) *m. gastrocnemius – caput mediale*; (2) *m. tibialis anterior*; (3) *m. peroneus longus*; (4) *m. extensor digitorum longus*; (5) *lig. patellae*
- D. desna golen – od spredaj (*crus*), (1) *m. extensor digitorum longus*; (2) *m. gastrocnemius – caput mediale*; (3) *m. peroneus longus*; (4) *m. tibialis anterior*; (5) *lig. patellae*
- E. leva golen – od spredaj (*crus*), (1) *m. tibialis anterior*; (2) *m. gastrocnemius – caput mediale*; (3) *m. peroneus longus*; (4) *m. extensor digitorum longus*; (5) *lig. patellae*.

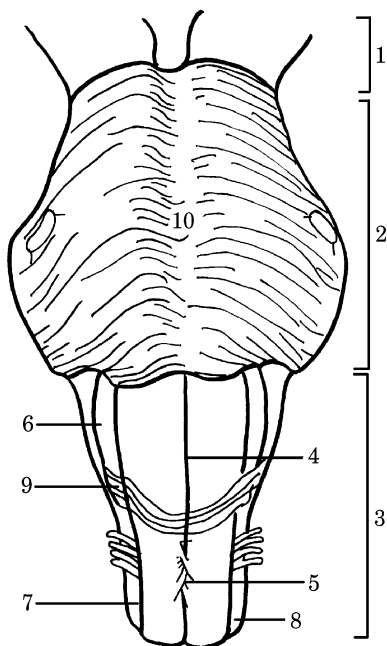
Skica 35

70. Pravilna legenda **skice 35** je:
- A. desna golen – od zadaj (*crus*), (1) *m. popliteus*; (2) *m. semimembranosus*; (3) *m. gastrocnemius: caput mediale et laterale*; (4)



- m. biceps femoris: caput longum et caput breve*; (5) *m. soleus*; (6) *tendo calcaneus*
- B. desna golen – od zadaj (*crus*), (1) *m. biceps femoris: caput longum et caput breve*; (2) *m. semimembranosus*; (3) *m. soleus*; (4) *m. popliteus*; (5) *m. gastrocnemius: caput mediale et laterale*; (6) *tendo calcaneus*
- C. desna golen – od zadaj (*crus*), (1) *m. biceps femoris: caput longum et caput breve*; (2) *m. soleus*; (3) *m. gastrocnemius: caput mediale et laterale*; (4) *m. popliteus*; (5) *m. semimembranosus*; (6) *tendo calcaneus*

- D. leva golen – od zadaj (*crus*), (1) *m. biceps femoris: caput longum et caput breve*; (2) *m. semimembranosus*; (3) *m. gastrocnemius: caput mediale et laterale*; (4) *m. popliteus*; (5) *m. soleus*; (6) *tendo calcaneus*
- E. desna golen – od zadaj (*crus*), (1) *m. biceps femoris: caput longum et caput breve*; (2) *m. semimembranosus*; (3) *m. gastrocnemius: caput mediale et laterale*; (4) *m. popliteus*; (5) *m. soleus*; (6) *tendo calcaneus*.



Skica 36

71. Pravilna legenda **skice 36** je:
- A. možgansko deblo – od spredaj, (2) *funiculus lateralis*; (4) *fissura mediana anterior*; (6) *oliva*; (8) *pons*; (10) *sulcus basilaris*
- B. možgansko deblo – od spredaj, (2) *oliva*; (4) *fissura mediana anterior*; (6) *pons*; (8) *funiculus lateralis*; (10) *sulcus basilaris*
- C. možgansko deblo – od spredaj, (2) *pons*; (4) *fissura mediana anterior*; (6) *oliva*; (8) *funiculus lateralis*; (10) *sulcus basilaris*
- D. možgansko deblo – od zadaj, (2) *pons*; (4) *fissura mediana anterior*; (6) *oliva*; (8) *funiculus lateralis*; (10) *sulcus basilaris*

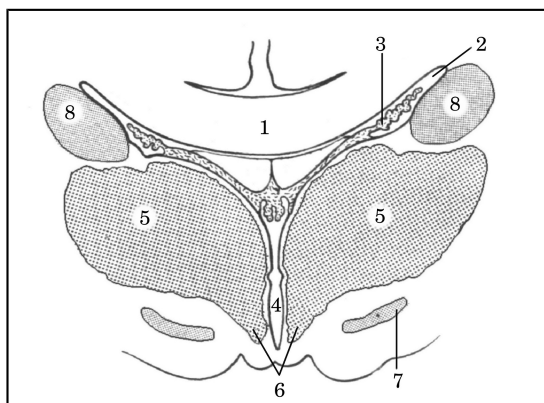
- E. možgansko deblo – od spredaj, (2) *pons*; (4) *sulcus basilaris*; (6) *oliva*; (8) *funiculus lateralis*; (10) *fissura mediana anterior*.

72. Pravilna legenda **skice 36** je:

- A. možgansko deblo – od spredaj, (1) *mesencephalon*; (3) *medulla oblongata*; (5) *decussatio pyramidum*; (7) *sulcus lateralis anterior*; (9) *fibrae arcuatae externae*
- B. možgansko deblo – od spredaj, (1) *decussatio pyramidum*; (3) *medulla oblongata*; (5) *mesencephalon*; (7) *sulcus lateralis anterior*; (9) *fibrae arcuatae externae*
- C. možgansko deblo – od spredaj, (1) *mesencephalon*; (3) *fibrae arcuatae externae*; (5) *decussatio pyramidum*; (7) *sulcus lateralis anterior*; (9) *medulla oblongata*
- D. možgansko deblo – od spredaj, (1) *decussatio pyramidum*; (3) *medulla oblongata*; (5) *mesencephalon*; (7) *sulcus lateralis anterior*; (9) *fibrae arcuatae externae*
- E. možgansko deblo – od zadaj, (1) *mesencephalon*; (3) *medulla oblongata*; (5) *decussatio pyramidum*; (7) *sulcus lateralis anterior*; (9) *fibrae arcuatae externae*.

73. Pravilna legenda **skice 37** je:

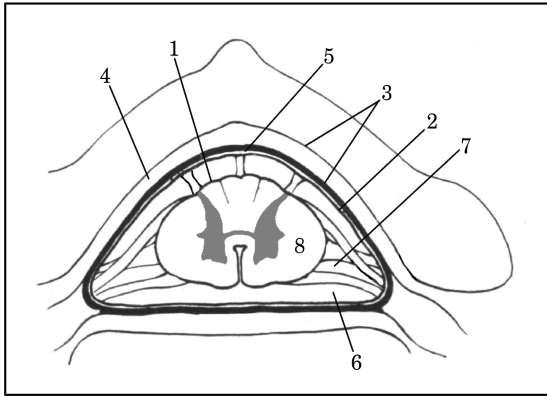
- A. (1) *substantia grisea*; (2) *substantia alba*; (3) *cornu anterius*; (4) *cornu laterale*; (5) *cornu posterius*; (6) *funiculus posterior*; (7) *funiculus anterior*; (8) *funiculus lateralis*
- B. (1) *substantia grisea*; (2) *substantia alba*; (3)



cornu posterius; (4) *cornu laterale*; (5) *cornu anterius*; (6) *funiculus posterior*; (7) *funiculus anterior*; (8) *funiculus lateralis*

- C. (1) *substantia grisea*; (2) *substantia alba*; (3) *cornu posterius*; (4) *cornu laterale*; (5) *cornu anterius*; (6) *funiculus anterior*; (7) *funiculus posterior*; (8) *funiculus lateralis*

- D. (1) *substantia alba*; (2) *substantia grisea*; (3)

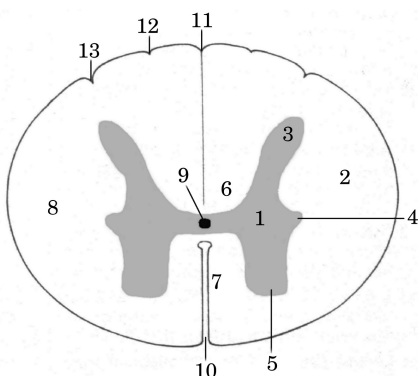


- cornu posterius; (4) *cornu laterale*; (5) *cornu anterius*; (6) *funiculus posterior*; (7) *funiculus anterior*; (8) *funiculus lateralis*
- E. (1) *substantia grisea*; (2) *substantia alba*; (3) *cornu laterale*; (4) *cornu posterius*; (5) *cornu anterius*; (6) *funiculus posterior*; (7) *funiculus anterior*; (8) *funiculus lateralis*.

Skica 37

74. Pravilna legenda **skice 37** je:
- A. (9) *canalis centralis*; (10) *fissura mediana anterior*; (11) *sulcus intermedius posterior*; (12) *sulcus medianus posterior*; (13) *sulcus lateralis posterior*
- B. (9) *canalis centralis*; (10) *fissura mediana anterior*; (11) *sulcus lateralis posterior*; (12) *sulcus intermedius posterior*; (13) *sulcus medianus posterior*
- C. (9) *canalis centralis*; (10) *fissura mediana anterior*; (11) *sulcus medianus posterior*; (12) *sulcus lateralis posterior*; (13) *sulcus intermedius posterior*
- D. (9) *sulcus intermedius posterior*; (10) *fissura mediana anterior*; (11) *sulcus medianus posterior*; (12) *sulcus lateralis posterior*; (13) *canalis centralis*
- E. (9) *canalis centralis*; (10) *fissura mediana anterior*; (11) *sulcus medianus posterior*; (12) *sulcus intermedius posterior*; (13) *sulcus lateralis posterior*.

Skica 38



75. Pravilna legenda **skice 38** je:

- A. (2) *ventriculus lateralis*; (4) *caput nuclei caudati*; (6) *hypothalamus*; (8) *ventriculus tertius*
- B. (2) *ventriculus lateralis*; (4) *ventriculus tertius*; (6) *hypothalamus*; (8) *caput nuclei caudati*
- C. (2) *hypothalamus*; (4) *ventriculus tertius*; (6) *ventriculus lateralis*; (8) *caput nuclei caudati*
- D. (2) *ventriculus lateralis*; (4) *hypothalamus*; (6) *ventriculus tertius*; (8) *caput nuclei caudati*
- E. (2) *ventriculus lateralis*; (4) *ventriculus tertius*; (6) *caput nuclei caudati*; (8) *hypothalamus*.

76. Pravilna legenda **skice 38** je:

- A. (1) *nucleus subthalamicus*; (3) *tela choroidea*; (5) *thalamus*; (7) *corpus callosum*
- B. (1) *corpus callosum*; (3) *tela choroidea*; (5) *thalamus*; (7) *nucleus subthalamicus*
- C. (1) *corpus callosum*; (3) *nucleus subthalamicus*; (5) *thalamus*; (7) *tela choroidea*
- D. (1) *corpus callosum*; (3) *thalamus*; (5) *tela choroidea*; (7) *nucleus subthalamicus*
- E. (1) *tela choroidea*; (3) *corpus callosum*; (5) *thalamus*; (7) *nucleus subthalamicus*.

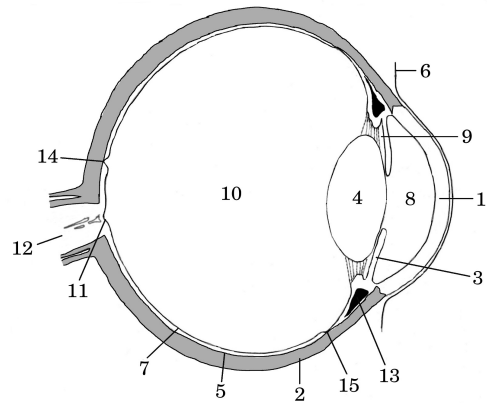
Skica 39

77. Pravilna legenda **skice 39** je:
- A. (1) *pia mater spinalis*; (2) *arachnoidea spinalis*; (3) *dura mater spinalis*; (4) *cavum epidurale*; (5) *cavum subdurale*; (6) *cavum subarachnoideale et liquor cerebrospinalis*; (7) *lig. denticulatum*
- B. (1) *pia mater spinalis*; (2) *arachnoidea spinalis*; (3) *dura mater spinalis*; (4) *cavum subarachnoideale et liquor cerebrospinalis*; (5) *cavum subdurale*; (6) *cavum epidurale*; (7) *lig. denticulatum*
- C. (1) *pia mater spinalis*; (2) *arachnoidea spinalis*; (3) *cavum epidurale*; (4) *dura mater spinalis*; (5) *cavum subdurale*; (6) *cavum subarachnoideale et liquor cerebrospinalis*; (7) *lig. denticulatum*
- D. (1) *arachnoidea spinalis*; (2) *pia mater spinalis*; (3) *dura mater spinalis*; (4) *cavum epidurale*; (5) *cavum subdurale*; (6) *cavum subarachnoideale et liquor cerebrospinalis*; (7) *lig. denticulatum*
- E. (1) *lig. denticulatum*; (2) *arachnoidea spinalis*; (3) *dura mater spinalis*; (4) *cavum epidurale*;

(5) *cavum subdurale*; (6) *cavum subarachnoidale et liquor cerebrospinalis*; (7) *pia mater spinalis*.

78. Pravilna legenda **skice 40** je:

- A. (1) *cornea*; (4) *retina*; (7) *lens*; (11) *discus n. optici*; (14) *fovea centralis et macula lutea*
- B. (1) *cornea*; (4) *lens*; (7) *retina*; (11) *fovea centralis et macula lutea*; (14) *discus n. optici*
- C. (1) *retina*; (4) *lens*; (7) *cornea*; (11) *discus n. optici*; (14) *fovea centralis et macula lutea*
- D. (1) *retina*; (4) *lens*; (7) *cornea*; (11) *discus n. optici*; (14) *fovea centralis et macula lutea*
- E. (1) *cornea*; (4) *lens*; (7) *retina*; (11) *discus n. optici*; (14) *fovea centralis et macula lutea*.



Skica 40

79. Pravilna legenda **skice 40** je:

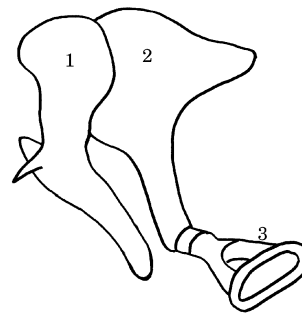
- A. (2) *ora serrata*; (5) *choroidea*; (12) *n. opticus*; (13) *corpus ciliare*; (15) *sclera*
- B. (2) *sclera*; (5) *n. opticus*; (12) *choroidea*; (13) *corpus ciliare*; (15) *ora serrata*
- C. (2) *sclera*; (5) *choroidea*; (12) *n. opticus*; (13) *corpus ciliare*; (15) *ora serrata*
- D. (2) *sclera*; (5) *choroidea*; (12) *n. opticus*; (13) *ora serrata*; (15) *corpus ciliare*
- E. (2) *sclera*; (5) *ora serrata*; (12) *n. opticus*; (13) *corpus ciliare*; (15) *choroidea*.

80. Pravilna legenda **skice 40** je:

- A. (3) *iris*; (6) *conjunctiva*; (8) *camera posterior bulbi*; (9) *camera anterior bulbi*; (10) *corpus vitreum*; (11) *discus n. optici*
- B. (3) *iris*; (6) *conjunctiva*; (8) *camera anterior bulbi*; (9) *camera posterior bulbi*; (10) *corpus vitreum*; (11) *discus n. optici*
- C. (3) *corpus vitreum*; (6) *conjunctiva*; (8) *camera anterior bulbi*; (9) *camera posterior bulbi*; (10) *iris*; (11) *discus n. optici*
- D. (3) *iris*; (6) *camera anterior bulbi*; (8) *conjunctiva*; (9) *camera posterior bulbi*; (10) *corpus vitreum*; (11) *discus n. optici*
- E. (3) *camera posterior bulbi*; (6) *conjunctiva*; (8) *camera anterior bulbi*; (9) *iris*; (10) *corpus vitreum*; (11) *discus n. optici*.

81. Pravilna legenda **skice 41** je:

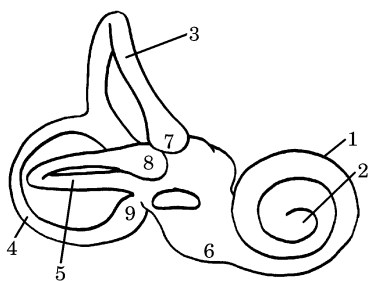
- A. (1) *ampulla ossea lateralis*; (2) *incus*; (3) *cupula cochleae*
- B. (1) *ampulla ossea lateralis*; (2) *incus*; (3) *stapes*
- C. (1) *ampulla ossea lateralis*; (2) *cupula cochleae*; (3) *stapes*
- D. (1) *malleus*; (2) *incus*; (3) *ampulla ossea lateralis*
- E. (1) *malleus*; (2) *incus*; (3) *stapes*.



Skica 41

82. Pravilna legenda **skice 42** je:
- (2) *cupula cochleae*; (4) *canalis semicircularis ossei posterior*; (6) *vestibulum*; (8) *ampulla ossea lateralis*
 - (2) *cupula cochleae*; (4) *ampulla ossea lateralis*; (6) *vestibulum*; (8) *canalis semicircularis ossei posterior*
 - (2) *ampulla ossea lateralis*; (4) *canalis semicircularis ossei posterior*; (6) *vestibulum*; (8) *cupula cochleae*
 - (2) *vestibulum*; (4) *canalis semicircularis ossei posterior*; (6) *cupula cochleae*; (8) *ampulla ossea lateralis*
 - (2) *cupula cochleae*; (4) *vestibulum*; (6) *canalis semicircularis ossei posterior*; (8) *ampulla ossea lateralis*.

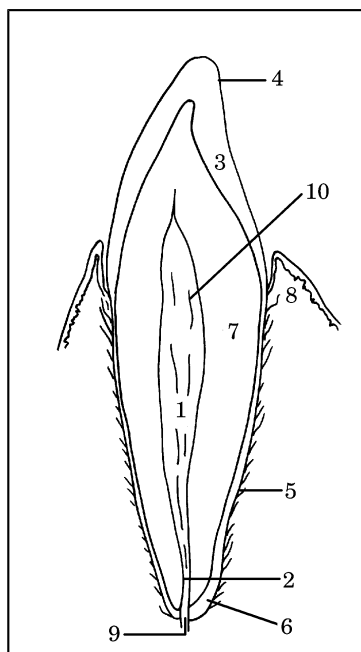
83. Pravilna legenda **skice 42** je:
- (1) *ampulla ossea posterior*; (3) *canalis semicircularis ossei anterior*; (5) *canalis semicircularis ossei lateralis*; (7) *ampulla ossea anterior*; (9) *cochlea*
 - (1) *cochlea*; (3) *ampulla ossea anterior*; (5) *canalis semicircularis ossei lateralis*; (7) *canalis semicircularis ossei anterior*; (9) *ampulla ossea posterior*
 - (1) *cochlea*; (3) *canalis semicircularis ossei anterior*; (5) *ampulla ossea posterior*; (7) *ampulla ossea anterior*; (9) *canalis semicircularis ossei lateralis*
 - (1) *cochlea*; (3) *canalis semicircularis ossei anterior*; (5) *canalis semicircularis ossei lateralis*; (7) *ampulla ossea anterior*; (9) *ampulla ossea posterior*
 - (1) *ampulla ossea anterior*; (3) *canalis semicircularis ossei anterior*; (5) *canalis semicircularis ossei lateralis*; (7) *cochlea*; (9) *ampulla ossea posterior*.



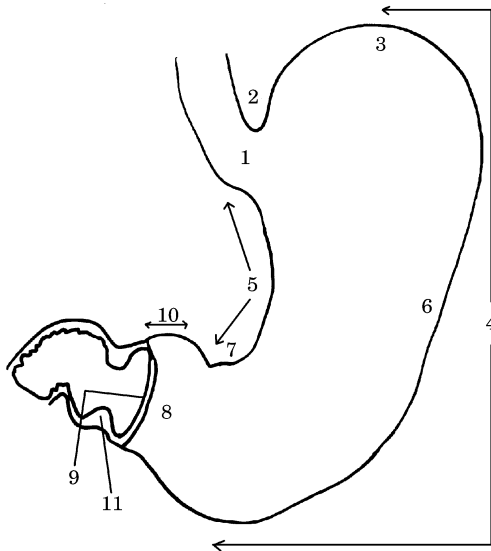
Skica 42

Skica 43

84. Pravilna legenda **skice 43** je:
- (2) *canalis radices dentis*; (4) *cementum*; (6) *cuticula dentis*; (8) *gingiva*; (10) *pulpa dentis*
 - (2) *canalis radices dentis*; (4) *cuticula dentis*; (6) *cementum*; (8) *gingiva*; (10) *pulpa dentis*
 - (2) *canalis radices dentis*; (4) *pulpa dentis*; (6) *cementum*; (8) *gingiva*; (10) *cuticula dentis*
 - (2) *gingiva*; (4) *cuticula dentis*; (6) *cementum*; (8) *canalis radices dentis*; (10) *pulpa dentis*
 - (2) *cementum*; (4) *cuticula dentis*; (6) *canalis radices dentis*; (8) *gingiva*; (10) *pulpa dentis*.



85. Pravilna legenda **skice 43** je:
- (1) *cavum dentis*; (3) *emalj – substantia adamantina*; (5) *periodontium*; (7) *dentinum*; (9) *foramen apicis dentis*
 - (1) *dentinum*; (3) *emalj – substantia adamantina*; (5) *periodontium*; (7) *cavum dentis*; (9) *foramen apicis dentis*
 - (1) *foramen apicis dentis*; (3) *emalj – substantia adamantina*; (5) *periodontium*; (7) *dentinum*; (9) *cavum dentis*
 - (1) *cavum dentis*; (3) *emalj – substantia adamantina*; (5) *dentinum*; (7) *periodontium*; (9) *foramen apicis dentis*
 - (1) *cavum dentis*; (3) *periodontium*; (5) *emalj – substantia adamantina*; (7) *dentinum*; (9) *foramen apicis dentis*.

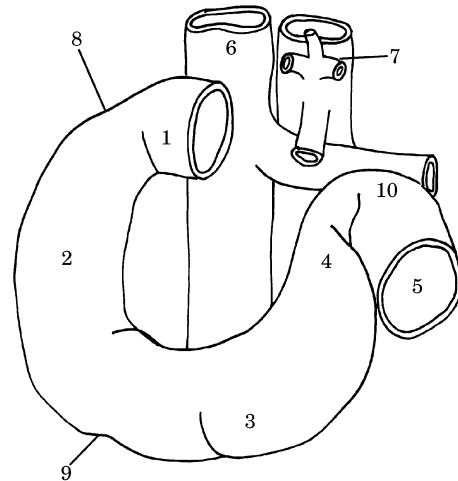


Skica 44

86. Pravilna legenda skice 44 je:
- A. (1) *cardia*; (3) *fundus*; (5) *curvatura minor*; (7) *incisura angularis*; (9) *canalis pyloricus*; (11) *m. sphincter pylori*
 - B. (1) *fundus*; (3) *cardia*; (5) *curvatura minor*; (7) *incisura angularis*; (9) *canalis pyloricus*; (11) *m. sphincter pylori*
 - C. (1) *cardia*; (3) *fundus*; (5) *incisura angularis*; (7) *curvatura minor*; (9) *canalis pyloricus*; (11) *m. sphincter pylori*
 - D. (1) *cardia*; (3) *fundus*; (5) *curvatura minor*; (7) *incisura angularis*; (9) *m. sphincter pylori*; (11) *canalis pyloricus*
 - E. (1) *canalis pyloricus*; (3) *fundus*; (5) *curvatura minor*; (7) *incisura angularis*; (9) *cardia*; (11) *m. sphincter pylori*.

87. Pravilna legenda skice 44 je:
- A. (2) *curvatura major*; (4) *incisura cardiaca*; (6) *corpus ventriculi*; (8) *antrum pyloricum*; (10) *pars pylorica*
 - B. (2) *incisura cardiaca*; (4) *curvatura major*; (6) *corpus ventriculi*; (8) *antrum pyloricum*; (10) *pars pylorica*
 - C. (2) *incisura cardiaca*; (4) *curvatura major*; (6) *corpus ventriculi*; (8) *pars pylorica*; (10) *antrum pyloricum*
 - D. (2) *incisura cardiaca*; (4) *curvatura major*; (6) *pars pylorica*; (8) *antrum pyloricum*; (10) *corpus ventriculi*

- E. (2) *incisura cardiaca*; (4) *antrum pyloricum*; (6) *corpus ventriculi*; (8) *curvatura major*; (10) *pars pylorica*.



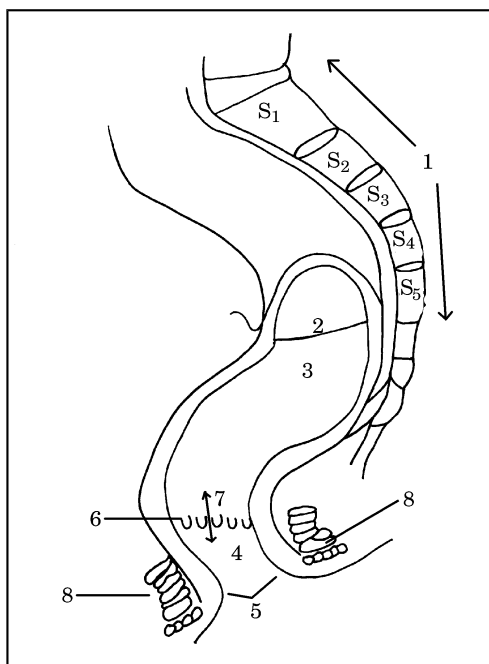
Skica 45

88. Pravilna legenda skice 45 je:
- A. dvanajstnik – od zadaj, (1) *pars superior*; (2) *pars descendens*; (3) *pars horizontalis*; (4) *pars ascendens*; (5) *jejunum*
 - B. dvanajstnik – od spredaj, (1) *pars descendens*; (2) *pars superior*; (3) *pars horizontalis*; (4) *pars ascendens*; (5) *jejunum*
 - C. dvanajstnik – od spredaj, (1) *pars superior*; (2) *pars horizontalis*; (3) *pars descendens*; (4) *pars ascendens*; (5) *jejunum*
 - D. dvanajstnik – od spredaj, (1) *pars superior*; (2) *pars descendens*; (3) *pars horizontalis*; (4) *pars ascendens*; (5) *jejunum*
 - E. dvanajstnik – od spredaj, (1) *pars superior*; (2) *pars descendens*; (3) *pars ascendens*; (4) *pars horizontalis*; (5) *jejunum*.
89. Pravilna legenda skice 45 je:
- A. dvanajstnik – od spredaj, (6) *v. cava inferior*; (7) *aorta abdominalis*; (8) *flexura duodeni superior*; (9) *flexura duodeni inferior*; (10) *flexura duodenojejunalis*
 - B. dvanajstnik – od zadaj, (6) *v. cava inferior*; (7) *aorta abdominalis*; (8) *flexura duodeni superior*; (9) *flexura duodeni inferior*; (10) *flexura duodenojejunalis*
 - C. dvanajstnik – od spredaj, (6) *aorta abdominalis*; (7) *v. cava inferior*; (8) *flexura duodeni superior*; (9) *flexura duodeni inferior*; (10) *flexura duodenojejunalis*

- D. dvanajstnik – od spredaj, (6) *v. cava inferior*; (7) *aorta abdominalis*; (8) *flexura duodeni inferior*; (9) *flexura duodeni superior*; (10) *flexura duodenojejunalis*
- E. dvanajstnik – od spredaj, (6) *v. cava inferior*; (7) *aorta abdominalis*; (8) *flexura duodenojejunalis*; (9) *flexura duodeni inferior*; (10) *flexura duodeni superior*.

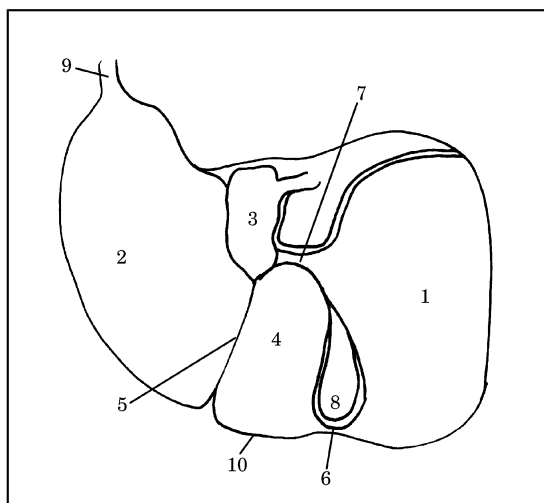
Skica 46

90. Pravilna legenda **skice 46** je:
- A. (1) *os sacrum*; (2) *plica transversales recti*; (3) *ampula recti*; (4) *canalis analis*; (5) *anus*; (6) *columnae anales*; (7) *zona hemorrhoidalis*; (8) *m. sphincter ani externus*
- B. (1) *os sacrum*; (2) *plica transversales recti*; (3) *ampula recti*; (4) *anus*; (5) *canalis analis*; (6) *columnae anales*; (7) *zona hemorrhoidalis*; (8) *m. sphincter ani externus*
- C. (1) *os sacrum*; (2) *plica transversales recti*;



- (3) *canalis analis*; (4) *ampula recti*; (5) *anus*;
(6) *columnae anales*; (7) *zona hemorrhoidalis*;
(8) *m. sphincter ani externus*
- D. (1) *os sacrum*; (2) *m. sphincter ani externus*;
(3) *ampula recti*; (4) *canalis analis*; (5) *anus*;
(6) *columnae anales*; (7) *zona hemorrhoidalis*;
(8) *plica transversales recti*
- E. (1) *os sacrum*; (2) *plica transversales recti*;
(4) *canalis analis*; (5) *anus*; (6) *columnae*

anales; (3) *zona hemorrhoidalis*; (7) *ampula recti*; (8) *m. sphincter ani externus*.



Skica 47

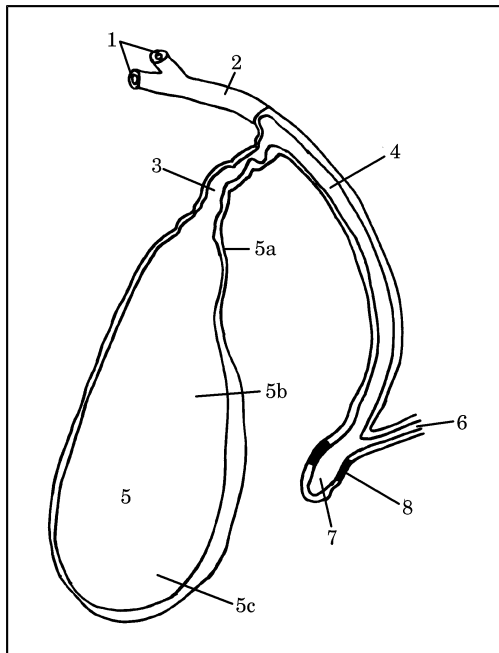
91. Pravilna legenda **skice 47** je:
- A. (1) *lobus hepaticus sinister*; (2) *lobus hepaticus dexter*; (3) *lobus caudatus*; (4) *lobus quadratus*; (10) *margo inferior*
- B. (1) *lobus hepaticus dexter*; (2) *lobus quadratus*; (3) *lobus caudatus*; (4) *lobus hepaticus sinister*; (10) *margo inferior*
- C. (1) *lobus hepaticus dexter*; (2) *lobus hepaticus sinister*; (3) *lobus caudatus*; (4) *lobus quadratus*; (10) *margo inferior*
- D. (1) *lobus hepaticus dexter*; (2) *lobus hepaticus sinister*; (3) *lobus quadratus*; (4) *lobus caudatus*; (10) *margo inferior*
- E. (1) *lobus hepaticus dexter*; (2) *lobus hepaticus sinister*; (3) *margo inferior*; (4) *lobus quadratus*; (10) *lobus caudatus*.
92. Pravilna legenda **skice 47** je:
- A. (5) *fissura sagittalis dextra*; (6) *lig. teres hepatis*; (7) *porta hepatis*; (8) *fossa vesicae felleae*; (9) *appendix fibrosa hepatis*
- B. (5) *fissura sagittalis sinistra (lig. teres hepatis)*; (6) *porta hepatis*; (7) *fissura sagittalis dextra*; (8) *fossa vesicae felleae*; (9) *appendix fibrosa hepatis*
- C. (5) *fissura sagittalis sinistra*; (6) *appendix fibrosa hepatis*; (7) *porta hepatis*; (8) *fossa vesicae felleae*; (9) *fissura sagittalis dextra*
- D. (5) *fissura sagittalis sinistra*; (6) *fissura sagittalis dextra*; (7) *porta hepatis*; (8) *appendix fibrosa hepatis*; (9) *fossa vesicae felleae*

- E. (5) *lig. teres hepatis*; (6) *fissura sagittalis dextra*; (7) *porta hepatis*; (8) *fossa vesicae felleae*; (9) *appendix fibrosa hepatis*.

Skica 48

93. Pravilna legenda **skice 48** je:

- A. (1) *ductus hepaticus sinister et dexter*; (2) *ductus hepaticus communis*; (3) *ductus cysticus*; (4) *ductus choledochus*; (5) *vesica fellea* (a) *collum*, (b) *corpus*, (c) *fundus*; (6) *ductus pancreaticus*; (7) *ampula hepatopancreatica*; (8) *m. sphincter ampullae*

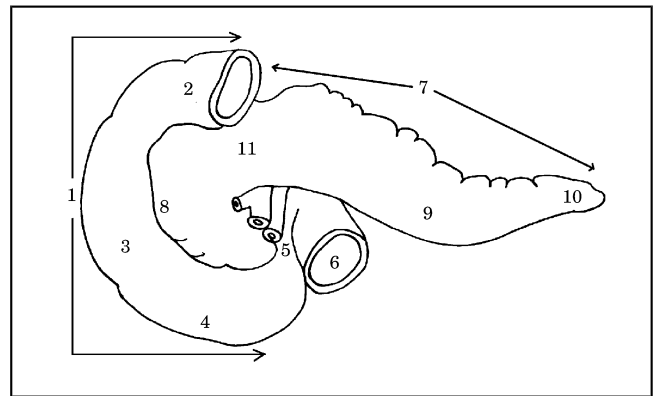


- B. (1) *ductus hepaticus sinister et dexter*; (2) *ductus cysticus*; (3) *ductus hepaticus communis*; (4) *ductus choledochus*; (5) *vesica fellea* (a) *collum*, (b) *corpus*, (c) *fundus*; (6) *ductus pancreaticus*; (7) *ampula hepatopancreatica*; (8) *Odijev sfinkter*
- C. (1) *ductus hepaticus sinister et dexter*; (2) *ductus choledochus*; (3) *ductus cysticus*; (4) *ductus hepaticus communis*; (5) *vesica fellea* (a) *collum*, (b) *corpus*, (c) *fundus*; (6) *ductus pancreaticus*; (7) *ampula hepatopancreatica*; (8) *m. sphincter ampullae*
- D. (1) *ductus hepaticus sinister et dexter*; (2) *ductus pancreaticus*; (3) *ductus cysticus*; (4) *ductus choledochus*; (5) *vesica fellea* (a) *collum*, (b) *corpus*, (c) *fundus*; (6) *ductus hepaticus communis*; (7) *ampula hepatopancreatica*; (8) *m. sphincter ampullae*

- E. (1) *ductus hepaticus sinister et dexter*; (2) *ductus hepaticus communis*; (3) *ductus cysticus*; (4) *ductus choledochus*; (5) *vesica fellea* (a) *corpus*, (b) *collum*, (c) *fundus*; (6) *ductus pancreaticus*; (7) *ampula hepatopancreatica*; (8) *Odijev sfinkter*.

94. Pravilna legenda **skice 49** je:

- A. dvanajstnik in trebušna slinavka – od zadaj, (1) *duodenum*; (2) *pars superior*; (3) *pars descendens*; (4) *pars horizontalis*; (5) *pars ascendens*
- B. dvanajstnik in trebušna slinavka – od spredaj, (1) *duodenum*; (2) *pars superior*; (3) *pars descendens*; (4) *pars horizontalis*; (5) *pars ascendens*
- C. dvanajstnik in trebušna slinavka – od spredaj, (1) *duodenum*; (2) *pars descendens*; (3) *pars superior*; (4) *pars horizontalis*; (5) *pars ascendens*
- D. dvanajstnik in trebušna slinavka – od spredaj, (1) *duodenum*; (2) *pars horizontalis*; (3) *pars descendens*; (4) *pars superior*; (5) *pars ascendens*
- E. dvanajstnik in trebušna slinavka – od zadaj, (1) *duodenum*; (2) *pars ascendens*; (3) *pars descendens*; (4) *pars horizontalis*; (5) *pars superior*.

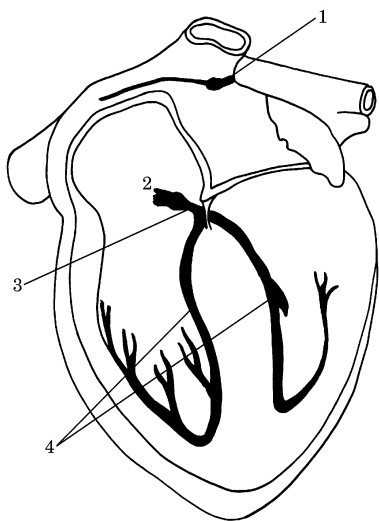


Skica 49

95. Pravilna legenda **skice 49** je:

- A. dvanajstnik in trebušna slinavka – od spredaj, (6) *jejunum*; (7) *pancreas*; (8) *corpus pancreatis*; (9) *caput pancreatis*; (10) *cauda pancreatis*; (11) *collum pancreatis*
- B. dvanajstnik in trebušna slinavka – od zadaj, (6) *jejunum*; (7) *pancreas*; (8) *caput pancreatis*; (9) *corpus pancreatis*; (10) *cauda pancreatis*; (11) *collum pancreatis*

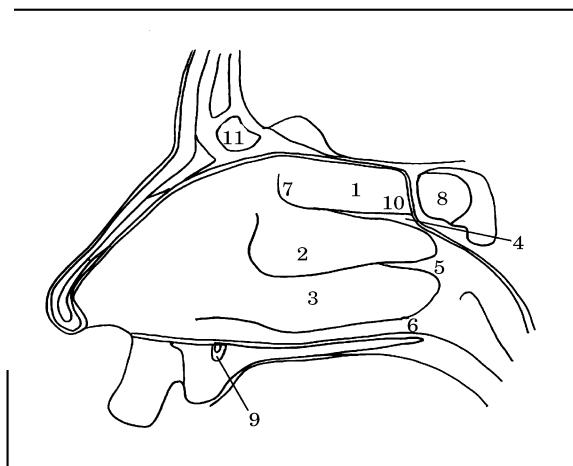
- C. dvanajstnik in trebušna slinavka – od zadaj, (6) jejunum; (7) pancreas; (8) collum pancreatis; (9) corpus pancreatis; (10) cauda pancreatis; (11) caput pancreatis
- D. dvanajstnik in trebušna slinavka – od spredaj, (6) jejunum; (7) pancreas; (8) caput pancreatis; (9) corpus pancreatis; (10) cauda pancreatis; (11) collum pancreatis
- E. dvanajstnik in trebušna slinavka – od spredaj, (6) jejunum; (7) pancreas; (8) caput pancreatis; (9) cauda pancreatis; (10) corpus pancreatis; (11) collum pancreatis.



Skica 50

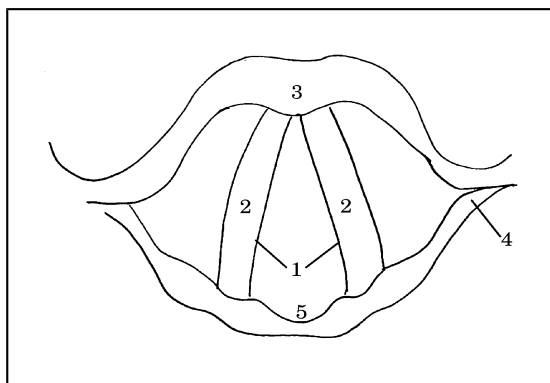
96. Pravilna legenda **skice 50** je:
- A. (1) nodus atrioventricularis; (2) nodus sinuatrialis; (3) fasciculus atrioventricularis; (4) crus dextrum et sinistrum
- B. (1) nodus sinuatrialis; (2) crus dextrum et sinistrum; (3) fasciculus atrioventricularis; (4) nodus atrioventricularis
- C. (1) nodus sinuatrialis; (2) nodus atrioventricularis; (3) fasciculus atrioventricularis; (4) crus dextrum et sinistrum
- D. (1) nodus sinuatrialis; (2) nodus atrioventricularis; (3) crus dextrum et sinistrum; (4) fasciculus atrioventricularis
- E. (1) fasciculus atrioventricularis; (2) nodus atrioventricularis; (3) nodus sinuatrialis; (4) crus dextrum et sinistrum.

97. Pravilna legenda **skice 51** je:
- A. (1) concha nasalis superior; (2) concha nasalis inferior; (3) concha nasalis media; (4) meatus nasi superior; (5) meatus nasi medius; (6) meatus nasi inferior
- B. (1) concha nasalis media; (2) concha nasalis superior; (3) concha nasalis inferior; (4) meatus nasi superior; (5) meatus nasi medius; (6) meatus nasi inferior
- C. (1) concha nasalis superior; (2) concha nasalis media; (3) concha nasalis inferior; (4) meatus nasi medius; (5) meatus nasi superior; (6) meatus nasi inferior
- D. (1) concha nasalis superior; (2) concha nasalis media; (3) concha nasalis inferior; (4) meatus nasi superior; (5) meatus nasi inferior; (6) meatus nasi medius
- E. (1) concha nasalis superior; (2) concha nasalis media; (3) concha nasalis inferior; (4) meatus nasi superior; (5) meatus nasi medius; (6) meatus nasi inferior.



Skica 51

98. Pravilna legenda **skice 51** je:
- A. (7) regio olfactoria; (8) sinus sphenoidalis; (9) ductus incisius; (10) recessus sphenoethmoidalis; (11) sinus frontalis
- B. (7) sinus sphenoidalis; (8) regio olfactoria; (9) ductus incisius; (10) recessus sphenoethmoidalis; (11) sinus frontalis
- C. (7) regio olfactoria; (8) ductus incisius; (9) sinus sphenoidalis; (10) recessus sphenoethmoidalis; (11) sinus frontalis
- D. (7) regio olfactoria; (8) recessus sphenoethmoidalis; (9) ductus incisius; (10) sinus sphenoidalis; (11) sinus frontalis
- E. (7) regio olfactoria; (8) sinus frontalis; (9) ductus incisius; (10) recessus sphenoethmoidalis; (11) sinus sphenoidalis.



Skica 52

99. Pravilna legenda **skice 52** je:

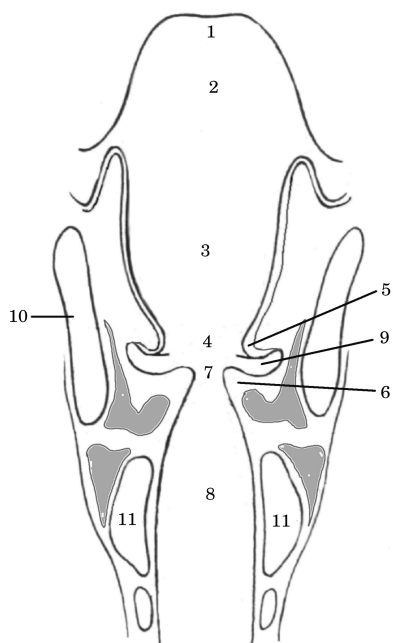
- A. grlo – od zgoraj, (1) *cartilago thyroidea*; (2) *plica vocalis*; (3) *rima glottidis*; (4) *cartilago cricoidea*; (5) *incisura interarytenoidea*
- B. grlo – od spodaj, (1) *rima glottidis*; (2) *plica vocalis*; (3) *cartilago cricoidea*; (4) *cartilago thyroidea*; (5) *incisura interarytenoidea*
- C. grlo – od zgoraj, (1) *rima glottidis*; (2) *incisura interarytenoidea*; (3) *cartilago thyroidea*; (4) *cartilago cricoidea*; (5) *plica vocalis*
- D. grlo – od zgoraj, (1) *rima glottidis*; (2) *plica vocalis*; (3) *cartilago thyroidea*; (4) *cartilago cricoidea*; (5) *incisura interarytenoidea*
- E. grlo – od spodaj, (1) *rima glottidis*; (2) *plica vocalis*; (3) *cartilago thyroidea*; (4) *cartilago cricoidea*; (5) *incisura interarytenoidea*.

100. Pravilna legenda **skice 53** je:

- A. (1) *epiglottis*; (3) *plica vestibularis*; (5) *vestibulum*; (7) *rima glottidis*; (10) *cartilago thyroidea*; (11) *cartilago cricoidea*
- B. (1) *epiglottis*; (3) *vestibulum*; (5) *plica vestibularis*; (7) *rima glottidis*; (10) *cartilago thyroidea*; (11) *cartilago cricoidea*
- C. (1) *rima glottidis*; (3) *vestibulum*; (5) *plica vestibularis*; (7) *epiglottis*; (10) *cartilago thyroidea*; (11) *cartilago cricoidea*
- D. (1) *epiglottis*; (3) *vestibulum*; (5) *plica vestibularis*; (7) *rima glottidis*; (10) *cartilago cricoidea*; (11) *cartilago thyroidea*
- E. (1) *plica vestibularis*; (3) *vestibulum*; (5) *epiglottis*; (7) *rima glottidis*; (10) *cartilago thyroidea*; (11) *cartilago cricoidea*.

101. Pravilna legenda **skice 53** je:

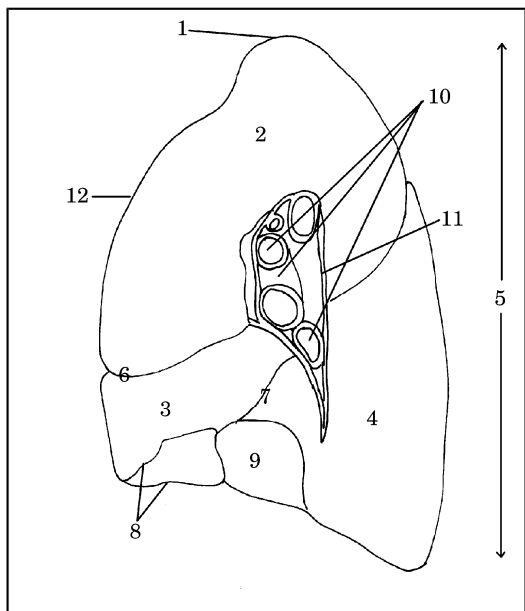
- A. (1) *epiglottis*; (2) *aditus laryngis*; (4) *rima vestibuli*; (6) *plica vocalis*; (8) *cavum infraglotticum*; (9) *ventriculus*
- B. (1) *rima vestibuli*; (2) *aditus laryngis*; (3) *vestibulum*; (4) *epiglottis*; (5) *plica vestibularis*; (6) *plica vocalis*; (7) *rima glottidis*; (8) *cavum infraglotticum*; (9) *ventriculus*; (10) *cartilago thyroidea*; (11) *cartilago cricoidea*
- C. (1) *epiglottis*; (2) *aditus laryngis*; (4) *cavum infraglotticum*; (6) *plica vocalis*; (8) *rima vestibuli*; (9) *ventriculus*
- D. (1) *epiglottis*; (2) *ventriculus*; (4) *rima vestibuli*; (6) *plica vocalis*; (8) *cavum infraglotticum*; (9) *aditus laryngis*
- E. (1) *plica vocalis*; (2) *aditus laryngis*; (4) *rima vestibuli*; (6) *epiglottis*; (8) *cavum infraglotticum*; (9) *ventriculus*.



Skica 53

102. Pravilna legenda skice 54 je:

- A. desna pljuča – medialna stran, (2) lobus superior; (3) lobus medius; (4) lobus inferior; (6) fissura obliqua; (7) fissura horizontalis
- B. desna pljuča – lateralna stran, (2) lobus superior; (3) lobus medius; (4) lobus inferior; (6) fissura horizontalis; (7) fissura obliqua
- C. desna pljuča – medialna stran, (2) lobus superior; (3) lobus medius; (4) lobus inferior; (6) fissura horizontalis; (7) fissura obliqua
- D. desna pljuča – medialna stran, (2) lobus superior; (3) lobus inferior; (4) lobus medius; (6) fissura horizontalis; (7) fissura obliqua
- E. desna pljuča – medialna stran, (2) lobus inferior; (3) lobus medius; (4) lobus superior; (6) fissura horizontalis; (7) fissura obliqua.



Skica 54

103. Pravilna legenda skice 54 je:

- A. desna pljuča – lateralna stran, (1) apex; (5) facies mediastinalis; (6) fissura horizontalis; (8) margo inferior; (9) facies diaphragmatica; (10) radix pulmonalis; (11) hilus pulmonalis; (12) margo anterior
- B. desna pljuča – medialna stran, (1) apex; (5) facies diaphragmatica; (6) fissura horizontalis; (8) margo inferior; (9) facies mediastinalis; (10) radix pulmonalis; (11) hilus pulmonalis; (12) margo anterior
- C. desna pljuča – medialna stran, (1) margo anterior; (5) facies mediastinalis; (6) fissura horizontalis; (8) margo inferior; (9) facies diaphragmatica; (10) radix pulmonalis; (11) hilus pulmonalis; (12) apex
- D. desna pljuča – medialna stran, (1) apex; (5) facies mediastinalis; (6) fissura horizontalis; (8) margo inferior; (9) facies diaphragmatica; (10) radix pulmonalis; (11) hilus pulmonalis; (12) margo anterior

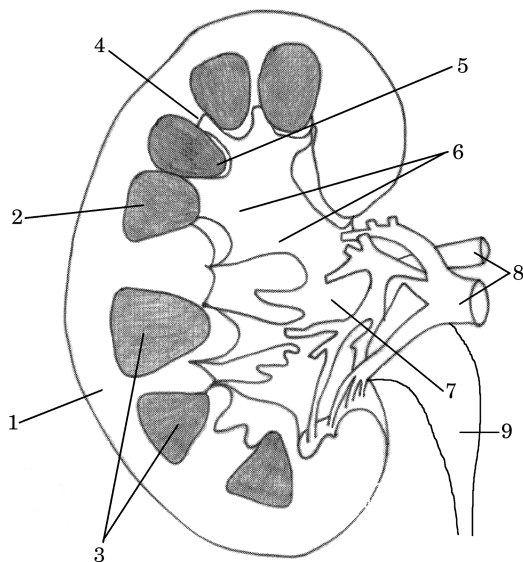
- E. desna pljuča – medialna stran, (1) apex; (5) facies mediastinalis; (6) fissura horizontalis; (8) margo anterior; (9) facies diaphragmatica; (10) radix pulmonalis; (11) hilus pulmonalis; (12) margo inferior.

104. Pravilna legenda skice 55 je:

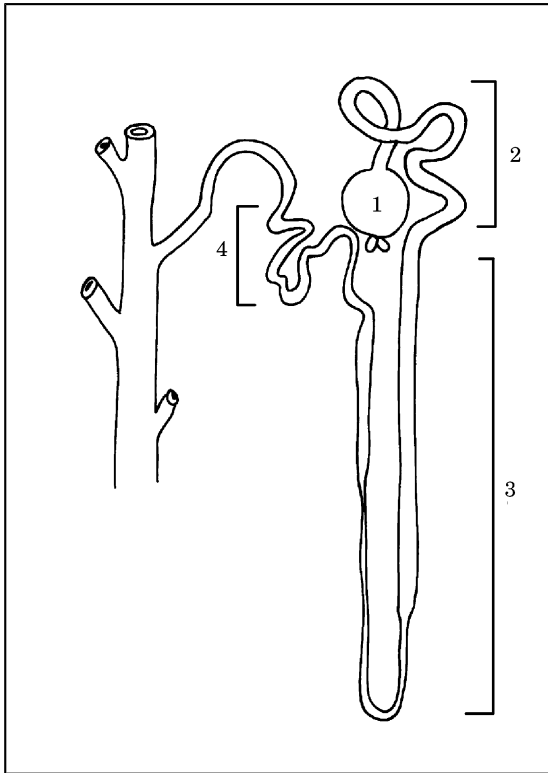
- A. (1) cortex renalis; (2) medulla renalis; (3) pyramides renales; (4) columnae renales; (5) papillae renales; (6) calices renales minores et majores; (7) pelvis renalis; (8) a. et v. renalis; (9) ureter
- B. (1) medulla renalis; (2) cortex renalis; (3) pyramides renales; (4) columnae renales; (5) papillae renales; (6) calices renales minores et majores; (7) pelvis renalis; (8) a. et v. renalis; (9) ureter
- C. (1) cortex renalis; (2) medulla renalis; (3) pyramides renales; (4) papillae renales; (5) columnae renales; (6) calices renales minores et majores; (7) pelvis renalis; (8) a. et v. renalis; (9) ureter
- D. (1) cortex renalis; (2) medulla renalis; (3) pyramides renales; (4) columnae renales; (5) calices renales minores et majores; (6) papillae

renales; (7) pelvis renalis; (8) a. et v. renalis; (9) ureter

- E. (1) *cortex renis*; (2) *medulla renis*; (3) *pyramides renales*; (4) *pelvis renalis*; (5) *papillae renales*; (6) *calices renales minores et majores*; (7) *columnae renales*; (8) *a. et v. renalis*; (9) *ureter*.



Skica 55



Skica 56

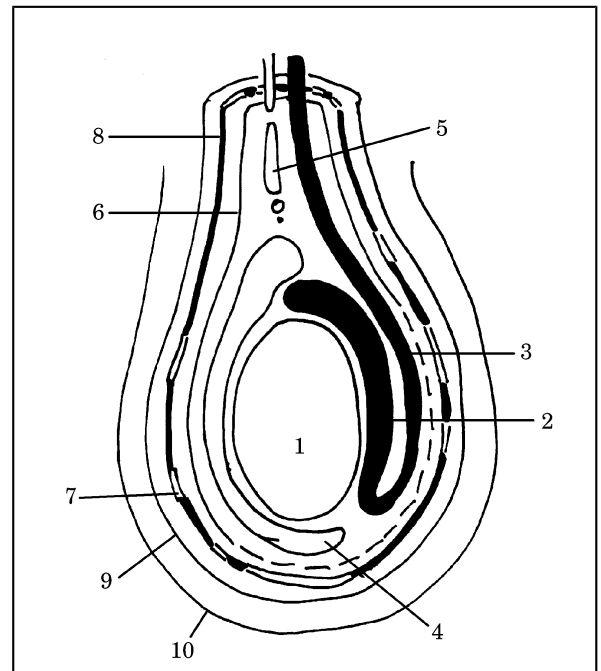
105. Pravilna legenda skice 56 je:

- A. (1) corpusculum renis; (2) tubuli renales contorti distales; (3) tubuli renales recti; (4) tubuli renales contorti proximales
- B. (1) corpusculum renis; (2) tubuli renales recti; (3) tubuli renales contorti proximales; (4) tubuli renales contorti distales
- C. (1) corpusculum renis; (2) tubuli renales contorti proximales; (3) tubuli renales contorti distales; (4) tubuli renales recti
- D. (1) corpusculum renis; (2) tubuli renales contorti proximales; (3) tubuli renales recti; (4) tubuli renales contorti distales
- E. (1) tubuli renales contorti proximales; (2) corpusculum renis; (3) tubuli renales recti; (4) tubuli renales contorti distales.

106. Pravilna legenda skice 57 je:

- A. (1) testis; (3) ductus deferens; (5) vestigium processus vaginalis; (7) fascia spermatica externa; (9) fascia cremasterica
- B. (1) testis; (3) ductus deferens; (5) vestigium processus vaginalis; (7) fascia cremasterica; (9) fascia spermatica externa

- C. (1) testis; (3) vestigium processus vaginalis; (5) ductus deferens; (7) fascia cremasterica; (9) fascia spermatica externa
- D. (1) ductus deferens; (3) testis; (5) vestigium processus vaginalis; (7) fascia cremasterica; (9) fascia spermatica externa
- E. (1) testis; (3) ductus deferens; (5) fascia cremasterica; (7) vestigium processus vaginalis; (9) fascia spermatica externa.

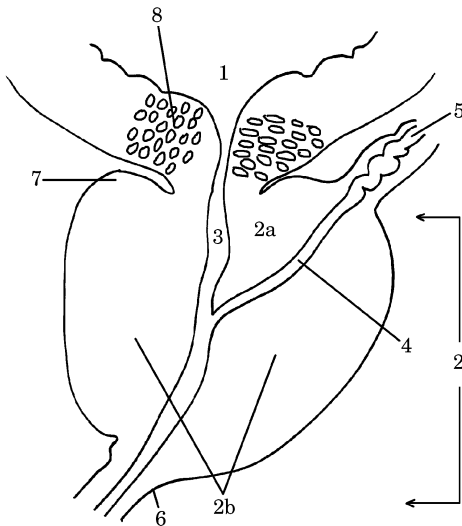


Skica 57

107. Pravilna legenda skice 57 je:

- A. (2) epididymis; (4) m. cremaster; (6) fascia spermatica interna; (8) tunica vaginalis testis; (10) integumentum commune

- B. (2) fascia spermatica interna; (4) tunica vaginalis testis; (6) epididymis; (8) m. cremaster; (10) integumentum commune
- C. (2) epididymis; (4) tunica vaginalis testis; (6) fascia spermatica interna; (8) m. cremaster; (10) integumentum commune
- D. (2) epididymis; (4) integumentum commune; (6) fascia spermatica interna; (8) m. cremaster; (10) tunica vaginalis testis
- E. (2) m. cremaster; (4) tunica vaginalis testis; (6) fascia spermatica interna; (8) epididymis; (10) integumentum commune.

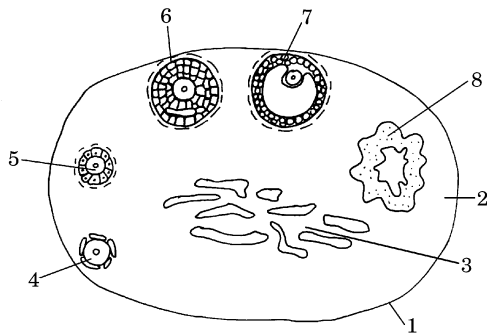


Skica 58

108. Pravilna legenda **skice 58** je:
- A. (2) prostata (a) lobus medius, (b) lobus dexter et sinister; (6) ductus ejaculatoris; (4) apex prostatae; (8) m. sphincter urethrae internus
 - B. (2) prostata (a) lobus medius, (b) lobus dexter et sinister; (4) ductus ejaculatoris; (6) apex prostatae; (8) m. sphincter urethrae internus
 - C. (2) prostata (a) lobus dexter et sinister, (b) lobus medius; (4) ductus ejaculatoris; (6) apex prostatae; (8) m. sphincter urethrae internus
 - D. (2) prostata (a) lobus medius, (b) lobus dexter et sinister; (4) m. sphincter urethrae internus; (6) apex prostatae; (8) ductus ejaculatoris
 - E. (2) apex prostatae; (4) ductus ejaculatoris; (6) prostata (a) lobus medius, (b) lobus dexter et sinister; (8) m. sphincter urethrae internus.

109. Pravilna legenda **skice 58** je:
- A. (1) vesica urinaria; (3) basis prostatae; (5) ductus deferens; (7) urethra (pars prostatica)
 - B. (1) vesica urinaria; (3) urethra (pars prostatica); (5) ductus deferens; (7) basis prostatae
 - C. (1) ductus deferens; (3) urethra (pars prostatica); (5) vesica urinaria; (7) basis prostatae
 - D. (1) vesica urinaria; (3) ductus deferens; (5) urethra (pars prostatica); (7) basis prostatae
 - E. (1) basis prostatae; (3) urethra (pars prostatica); (5) ductus deferens; (7) vesica urinaria.

110. Pravilna legenda **skice 59** je:
- A. (1) tunica albuginea; (2) substantia medullaris; (3) substantia corticalis; (4) folliculus ovaricus primordialis; (5) folliculus ovaricus primarius; (6) folliculus ovaricus secundarius; (7) folliculus ovaricus vesiculosus (Graafov folikel); (8) corpus luteum
 - B. (1) tunica albuginea; (2) substantia corticalis; (3) substantia medullaris; (4) folliculus ovaricus vesiculosus (Graafov folikel); (5) folliculus ovaricus primarius; (6) folliculus ovaricus secundarius; (7) folliculus ovaricus primordialis; (8) corpus luteum
 - C. (1) tunica albuginea; (2) substantia corticalis; (3) substantia medullaris; (4) folliculus ovaricus primordialis; (5) folliculus ovaricus secundarius; (6) folliculus ovaricus primarius; (7) folliculus ovaricus vesiculosus (Graafov folikel); (8) corpus luteum
 - D. (1) tunica albuginea; (2) substantia corticalis; (3) folliculus ovaricus vesiculosus (Graafov folikel); (4) folliculus ovaricus primordialis; (5) folliculus ovaricus primarius; (6) folliculus ovaricus secundarius; (7) substantia medullaris; (8) corpus luteum
 - E. (1) tunica albuginea; (2) substantia corticalis; (3) substantia medullaris; (4) folliculus ovaricus primordialis; (5) folliculus ovaricus primarius; (6) folliculus ovaricus secundarius; (7) folliculus ovaricus vesiculosus (Graafov folikel); (8) corpus luteum.



Skica 59

Skica 60

111. Pravilna legenda skice 60 je:

- A. (1) *symphysis pubica*; (2) *vesica urinaria*; (3) *urethra feminina*; (4) *uterus*; (5) *vagina*; (6) *rectum*; (7) *cavum Douglasi*; (8) *peritoneum viscerale*
- B. (1) *symphysis pubica*; (2) *vesica urinaria*; (3) *urethra feminina*; (4) *vagina*; (5) *uterus*; (6) *cavum Douglasi*; (7) *rectum*; (8) *peritoneum viscerale*
- C. (1) *symphysis pubica*; (2) *vesica urinaria*; (3) *urethra feminina*; (4) *vagina*; (5) *uterus*; (6) *rectum*; (7) *peritoneum viscerale*; (8) *cavum Douglasi*
- D. (1) *symphysis pubica*; (2) *vesica urinaria*; (3) *urethra feminina*; (4) *vagina*; (5) *uterus*; (6) *rectum*; (7) *cavum Douglasi*; (8) *peritoneum parietale*
- E. (1) *symphysis pubica*; (2) *urethra feminina*; (3) *vesica urinaria*; (4) *vagina*; (5) *uterus*; (6) *rectum*; (7) *cavum Douglasi*; (8) *peritoneum viscerale*.

112. Pravilna legenda skice 61 je:

- A. ščitnica – od spredaj, (1) *isthmus*; (2) *lobus pyramidalis*; (3) *lobus sinister*; (4) *lobus dexter*; (5) *cartilago thyroidea*; (6) *trachea*; (7) *os hyoideum*
- B. ščitnica – od zadaj, (1) *isthmus*; (2) *lobus pyramidalis*; (3) *lobus sinister*; (4) *lobus dexter*; (5) *cartilago thyroidea*; (6) *trachea*; (7) *os hyoideum*
- C. ščitnica – od spredaj, (1) *isthmus*; (2) *lobus pyramidalis*; (3) *lobus sinister*; (4) *lobus dexter*; (5) *cartilago thyroidea*; (6) *os hyoideum*; (7) *trachea*
- D. ščitnica – od zadaj, (1) *lobus pyramidalis*; (2) *isthmus*; (3) *lobus sinister*; (4) *lobus dexter*; (5) *cartilago thyroidea*; (6) *trachea*; (7) *os hyoideum*

- E. ščitnica – od spredaj, (1) *isthmus*; (2) *lobus pyramidalis*; (3) *lobus dexter*; (4) *lobus sinister*; (5) *cartilago thyroidea*; (6) *trachea*; (7) *os hyoideum*.

Skica 61

